

## CONVERSATIONS IN OPTIC NERVE AND RETINAL VASCULAR DISEASE

Joseph Sowka, OD, FAAO,  
Diplomate

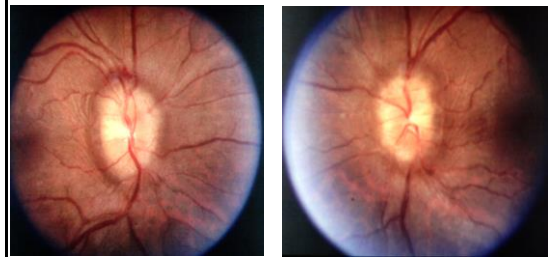


### DISCLOSURE:

*Dr. Joseph Sowka* is a member of the advisory boards for Novartis, Glaukos, Allergan, and B&L. Dr. Sowka has no direct financial interest in any of the diseases, products or instrumentation mentioned in this presentation.

### 28 YOF

- Presents with intermittent blurred vision & visual “blackouts”, intermittent diplopia, and chronic headache steadily worsening X 2 weeks
- MHx: “white coat hypertension”, shoulder injury X 6 mos
- Meds: Flexeril® 10 mg BID PRN
- Height / weight: 5’3”, 220 lbs.
- VA: OD 20/20, OS 20/20
- Pupils & motility: normal



What questions do you want to ask?  
What tests do you want to perform?

### 28 YOF

- Additional hx: Dull “ringing” in ears
- BP: 142/100
- SLE: unremarkable
- T<sub>A</sub>: OU 16 mm Hg
- VF: blind spot enlargement & nasal step defect OU
- Serology Normal
- Imaging: small ventricles, otherwise normal
- LP: O.P. = 510 mm H<sub>2</sub>O; all CSF studies normal
- DX: Pseudotumor cerebri (PTC)

### DEFINITION:



**PAPILLEDEMA: EDEMA OF THE OPTIC DISC, SPECIFICALLY RESULTING FROM ELEVATED INTRACRANIAL PRESSURE.**

## PAPILLEDEMA: SIGNS & SYMPTOMS

### Signs:

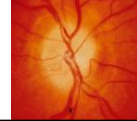
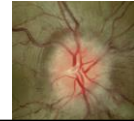
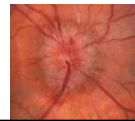
- bilateral disc edema
  - superior & inferior aspects of discs affected FIRST
  - obliteration of optic cup
  - hemorrhages common
  - absence of SVP
  - Paton's folds
- highly variable VF defects
  - enlarged blind spot (early)
  - arcuate defects and constricted (late)
- NO RAPD typically
- VA near normal

### Symptoms:

- Visual:
  - transient visual obscurations
  - intermittent horizontal diplopia
- General:
  - headache common
  - nausea & vomiting
  - dizziness
  - tinnitus

## PAPILLEDEMA TYPES:

- **Acute**
  - Hemorrhages, exudates, hyperemia, RNFL edema
- **Chronic**
  - Minimal hemorrhage/exudate. Collateral vessels may be present
- **Atrophic**
  - Eventually occurs if papilledema remains chronic. Optic disc pallor

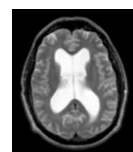
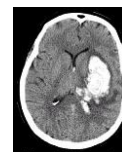
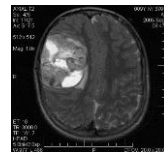


## PAPILLEDEMA PATHOPHYSIOLOGY

- **Disc edema results from axoplasmic stasis**
  - intracellular fluids, metabolic by-products accumulate and are regurgitated at the level of the optic nerve head
  - in papilledema, cerebral edema is effectively transmitted along the common meningeal sheaths of the brain and optic nerve producing an engorged, swollen disc.

## PAPILLEDEMA PATHOPHYSIOLOGY

- **Associated with intracranial abnormalities:**
  - increased brain volume (intracranial mass lesion)
  - increased intracranial blood volume
    - Intracranial hemorrhage
  - increased CSF volume
    - Hydrocephalus
    - Ventricular blockage by mass lesion



## PAPILLEDEMA MANAGEMENT

- **Rule out "swollen disc masqueraders"**
  - ultrasonography can be invaluable in differentiating ONHD
  - also consider color, margins, SVP, vasculature, etc.
- **Acute papilledema constitutes a medical emergency**
  - Immediate neuro-imaging to rule out an intracranial mass.
  - If imaging is normal, lumbar puncture to measure CSF pressure and exclude meningitis or other disease processes is necessary.
- **Atrophic papilledema with significant vision/field loss:**
  - urgent measures must be undertaken to prevent blindness
- **Papilledema accompanied by any neurologic abnormalities, fever or stiff neck:**
  - Possible serious underlying neurologic abnormality, intracranial infection or bleed requiring immediate medical attention.

## PTC VS. IIH

- **Pseudotumor Cerebri (PTC)**
  - Increased intracranial pressure in the absence of an intracranial mass lesion
  - Many causative agents have been identified
- **Idiopathic Intracranial Hypertension (IIH)**
  - Increased intracranial pressure without an identifiable cause
  - Young, obese females are at risk
- **Primary PTC**
  - IIH
- **Poor CFS drainage**

## PSEUDOTUMOR CEREBRI DIAGNOSIS

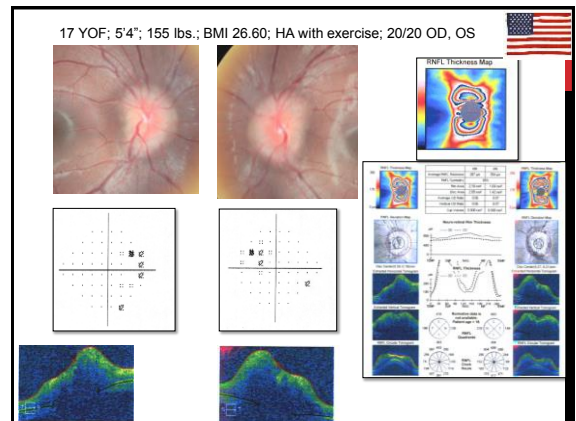
- Si/SX: consistent with increased ICP
- Papilledema
- Normal neurological examination
  - except for cranial nerve abnormalities
- Neuro-imaging: Normal without evidence of hydrocephalus, mass, or structural lesion, thrombosis
- Normal CSF composition
  - Elevated LP opening pressure
  - Adults: > 250 mm CSF
  - Children: > 280 mm CSF
  - > 250 mm CSF if not sedated/obese

## PSEUDOTUMOR CEREBRI MANAGEMENT

- No visual loss
  - Symptomatic headache therapy
  - Acetazolamide 500 mg tid
  - Weight reduction
- Mild visual loss
  - Acetazolamide 500 mg tid
    - Furosemide, Topiramate, Zonisamide
  - Weight reduction

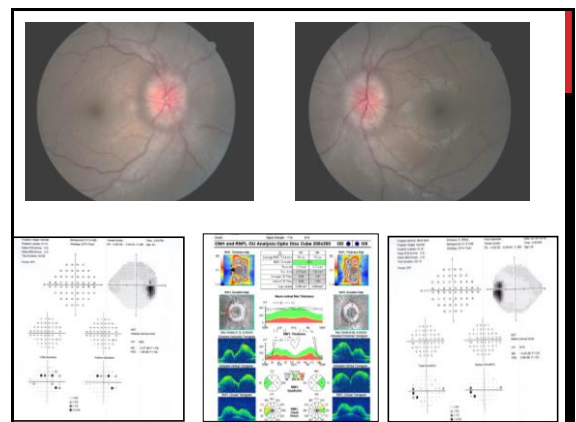
## PSEUDOTUMOR CEREBRI MANAGEMENT

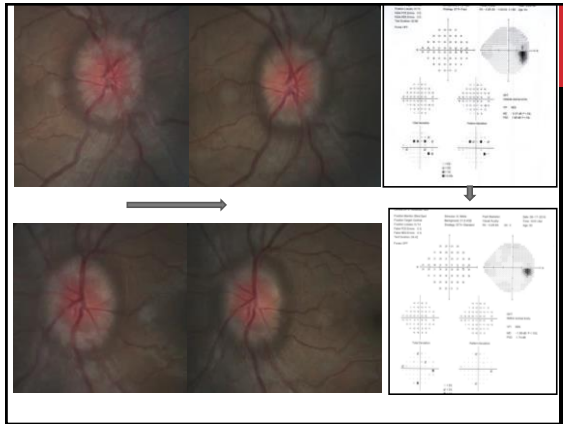
- No/ Mild visual loss
  - Prognosis
    - Excellent (all signs and symptoms, visual loss)
    - 6-9 months
  - Follow-up and visual fields
- Role of weight loss
  - Treat the primary problem
    - 10% weight loss
  - Prevent recurrence
    - Keep the weight down



## 33 YOF

- Horizontal diplopia
- Headache
- TVOs 20/day
- Denies OCP, tetracyclines, vitamin A
- Lost 10 lbs- headaches improved
- 118/72
- 5'5"; 160lbs; BMI 26.62

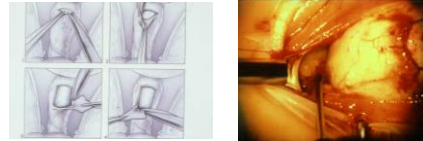




## PSEUDOTUMOR CEREBRI MANAGEMENT

### ▪ Severe, or progression of visual loss

- Optic nerve sheath decompression (ONSD)
- High-dose IV steroids and acetazolamide
- Lumboperitoneal shunt
  - Failed ONSD
  - Declined ONSD
  - Intractable headache



## REMEMBER

- Not all elevated discs are swollen, not all swollen discs are edematous, and not all edematous discs are papilledema
- True papilledema is a medical urgency and should be treated as such with a search for the cause.
- Many conditions can present with papilledema, including intracranial mass lesion, hydrocephalus, VST, PTC
- PTC is a diagnosis of EXCLUSION.



## ODE TO A SWOLLEN DISC

When you think the disc is swollen,  
The vessels north and south will appear stolen.

Not all elevated nerves are edematous,  
Just like not all snakes are venomous.

Your thoughts should go to papilledema,  
But infection and inflammation should still be in your schema.

MRI, MRV and LP,  
are soon to be.

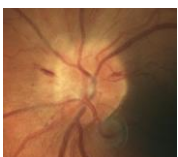
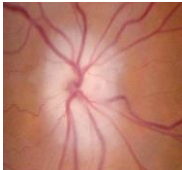Remember, pseudotumor is a diagnosis of exclusion,  
Female and firm does not make pseudotumor a forgone conclusion.

Brain tumors can exist when the pseudotumor profile is classic.

Do the evaluation so they don't end in a casket.

Joseph Sowka, OD

## WHICH IS BETTER? ONE OR TWO?

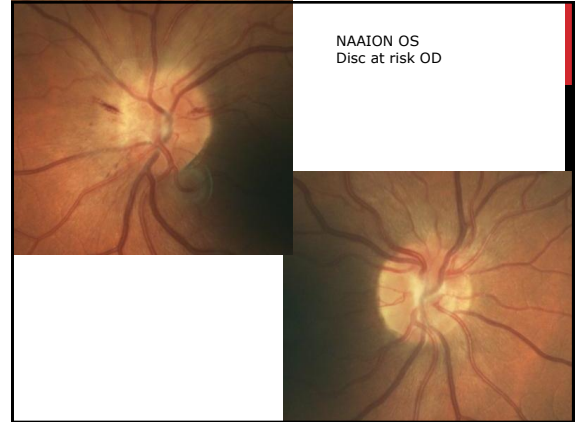
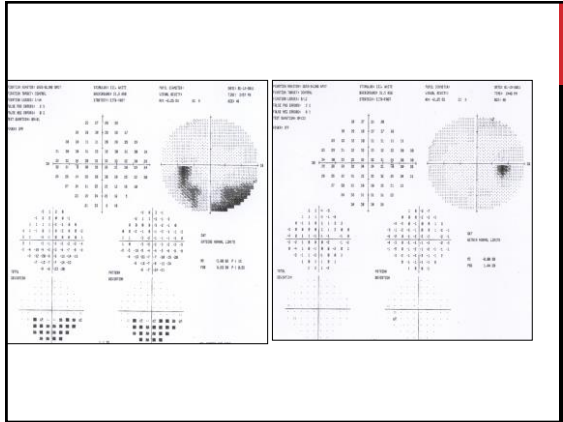


## 48 YOM

### Painless loss of visual field OS

- 20/20 OD, OS
- Noticed upon waking

Med Hx: Unremarkable, except for  
viral illness 3 weeks before



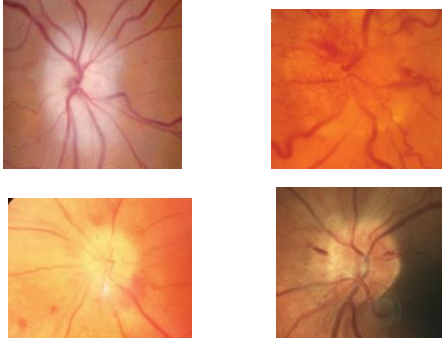
## 74 YOM

- Presents with 'worst headache of his life'
  - Sees: PA, ED physician; cardiologist; NP;
    - 3 week period
  - Histories: Eye ache; jaw pain, scalp pain, facial pain, somnolence; malaise; jaw claudication
  - Diagnoses: TMJ; Lyme disease
  - "vasculitis such as temporal arteritis highly unlikely", "Not GCA"
    - However, ESR and CRP ordered and elevated- never reviewed
  - Ultimately OD makes diagnosis
  - End result?

## ANTERIOR ISCHEMIC OPTIC NEUROPATHY

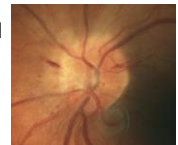
- Hypoperfusion of the posterior ciliary arterial supply to the anterior optic nerve head.
- May be arteritic (AAION) or non-arteritic (NAAION)
- Mechanical factors and atherosclerotic disease play a role in the non-arteritic form while vasculitis contributes in the arteritic form.
- Unilateral presentation but high incidence of subsequent contralateral involvement
  - AAION

## AAION VS NAAION



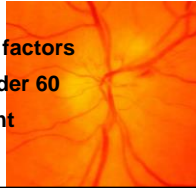
## NAAION

- Risk factors:
  - Hypertension, diabetes, atherosclerotic disease, small optic nerves
- Inferior field defects
- Hyperemic swollen nerve- disc at risk
- Progressive moderate vision loss with potential recovery
- Late 30s/ early 40s and beyond
- Painless



## AAION

- Pallid optic nerve swelling with flame hemorrhages, arteriole attenuation and NFL infarcts
- Pain (of some sort)
- Severe optic nerve dysfunction
- Visual field defects
- Giant cell arteritis/ PMR- risk factors
- Typically 70s, uncommon under 60
- High risk bilateral involvement



## DIAGNOSIS

- **Careful history: Must directly ask about nonvisual symptoms**
  - Headache (present in over 90%), scalp tenderness, jaw claudication (almost diagnostic), ear pain, arthralgias, temple pain and/or tenderness, malaise, intermittent fevers
- **Examination**
- **Laboratory studies**
  - Erythrocyte sedimentation rate
    - Lowered by statins and NSAIDS
  - C-reactive protein
    - Not affected by statins and NSAIDS
  - Elevated platelet count

## AAION

### DIAGNOSIS

**Prodrome, GCA symptoms**  
**Elevated ESR/CRP**  
 (combination of the two gives high specificity [97%])  
**Elevated platelet count**  
 (acute phase reactant)  
**Ophthalmoscopy**  
**Fluorescein angiography**  
**Temporal artery Biopsy**

### TREATMENT

**Prompt steroids and hydration**  
**Consider IV when vision loss present**

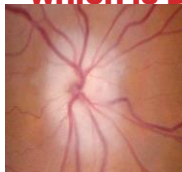
- Very effective in prevention of second eye
- Occasionally restores vision

## AAION VERSUS NAAION

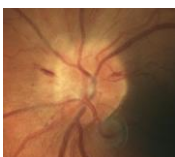
- **Think AAION>>>NAAION**
  - Systemic symptoms of GCA
  - TVOs/amaurosis
  - Elevated
    - ESR/CRP
    - Platelets
  - AION + cilioretinal artery occlusion
  - Evidence of posterior ciliary artery occlusion on FA
  - Early massive vision loss
  - Chalky white optic disc edema

Hayreh SS, Podhajsky PA, Zimmerman B. Occult giant cell arteritis: ocular manifestations. Am J Ophthalmol. 1998 Apr;125(4):521-6.

## WHICH IS BETTER? ONE OR TWO?



Bilaterally blind



Residual field loss, but otherwise not bothered

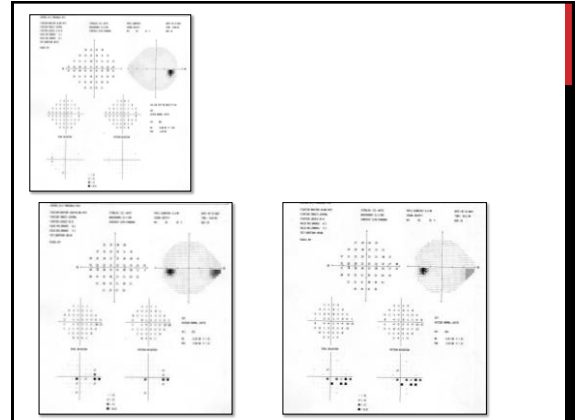
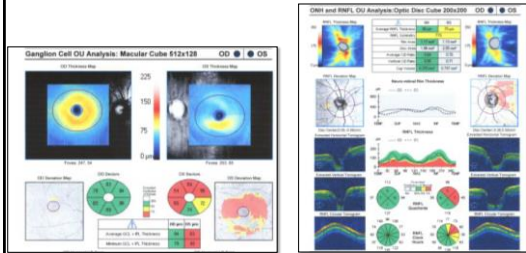
## ODE TO AN ISCHEMIC NERVE

When your patient's optic nerve is ischemic  
 You better hope the disc is hyperemic.  
 In Non-arteritic no treatment is needed  
 And life will rarely be impeded.  
 But if the disc is swollen and pale,  
 And vision is an epic fail  
 If the patient is sixties, seventies or eighties  
 You will feel heat like in Hades  
 ESR and CRP are required  
 And steroids must be acquired  
 Remember, when you see a choked disc  
 Always assess the giant cell risk

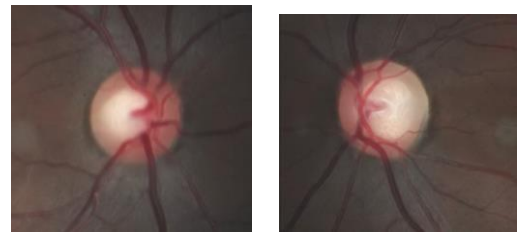
Joseph Sowka, OD

**29 YOF**

- Referred for glaucoma evaluation due to suspicious cupping- no complaints
- IOP 12 mm OD, 13 mm OS

**29 YOF**

- "Now let's get serious"
- 20/15 OD, OS
- IOP: 12 mm Hg OD, 13 mm OS
- CCT: 493 OD, 488 OS
- Gonio normal OU
- +RAPD OS



Segmental disc pallor OS

**OPTIC ATROPHY**

- **Primary optic atrophy**
  - Uniform nerve fiber degeneration, resulting in glial replacement but no architectural alteration of the optic nerve head.
  - Disc appears chalky white but the margins remain distinct and retinal vessels appear normal.
    - Trauma and compression (e.g. tumor) causes
- **Secondary optic atrophy**
  - Results from pathological chronic disc edema
    - malignant hypertension, papilledema, or infiltrative diseases like leukemia or sarcoidosis.

**OPTIC ATROPHY**

- **Consecutive optic atrophy**
  - Degenerative retinal conditions
    - Retinitis pigmentosa, pathological myopia and central retinal artery occlusion.
    - Pale, waxy disc, normal margins and marked attenuation of the arterioles.
- **Temporal disc pallor**
  - Toxic/ nutritional (bilateral) or demyelinating optic neuropathy (optic neuritis)



## OPTIC ATROPHY

### ▪ Numerous potential etiologies

- Infarction, infection, infiltration, inflammation, trauma, toxicity, metabolic dysfunction or direct compression of the nerve or chiasm

### ▪ Evaluation:

- MRI studies should be obtained of the orbits, the optic chiasm and the brain with and without contrast, fat suppression for orbits, in a high field scanning unit.
  - Contrast dye (gadolinium) is beneficial in discerning malignant lesions, demyelinating plaques indicative of multiple sclerosis.

All cases of optic nerve pallor/ optic atrophy must be investigated or explained

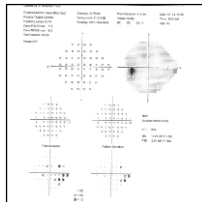
## OPTIC ATROPHY

### ▪ Systemic causes of optic atrophy

- sarcoidosis, tuberculosis, Behçet's disease, lymphoma, leukemia, systemic lupus erythematosus, nutritional or metabolic disorder (e.g. pernicious anemia, folate deficiency), syphilis, Lyme disease, and antiphospholipid antibody syndrome.
- **CBC, ESR, ACE, ANA, serum cardiolipin, serum homocysteine, serum B12 and folate levels, and rapid plasma regain (RPR) for syphilis.**
- Additionally, chest x-rays could prove helpful in suspected cases of TB or sarcoidosis.

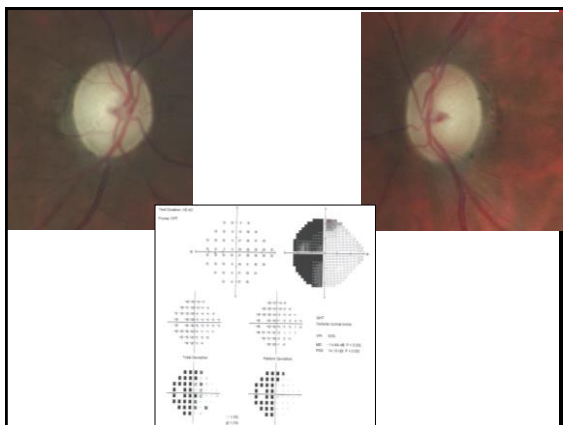
## 29 YOF- OUTCOME

- MRI orbits- normal (limited/ poor study)
- Repeat MRI brain- no lesions
- Lupus panel, ANA, DS DNA, ESR, metabolic panel, Vit B12/folate- normal
- RPR, HIV- non-reactive



## A FAMILY AFFAIR

- 56 YOFB
- Dx POAG OU 5 years ago
- Slowly progressive vision loss
- LP OD; 20/30 OS
- Used combo med- ran out months ago
- IOP: 19 mm OD, 18 mm OS
- CCT: 560; 544



TECHNIQUE: MRI of the orbits without and with gadolinium contrast:

Magnetic resonance imaging was performed on the brain utilizing sagittal, axial and coronal T1-weighted images. Subsequently, axial T2-weighted dual-echo images were acquired. Sequences were obtained without and with gadolinium contrast.

FINDINGS: The globes are normal in signal and morphology. The optic nerves have a normal MRI appearance. The extra-ocular muscles are normal in signal and morphology. The intraconal and extraconal fat planes are preserved. The visualized portions of the paranasal sinuses are well aerated.

There is a cystic and solid enhancing mass within the sella with dimensions of 36.06 mm in craniocaudal dimension and anterior posterior dimension of approximately 26.3 mm. The mass is partially cystic with septations but has solid enhancing components and elevates the optic chiasm.

#### IMPRESSION:

ENHANCING CYSTIC SEPTATED MASS WITHIN THE ADENOHYPHYSIS OF THE PITUITARY WITH DIMENSIONS OF 36.06 MM IN CRANIOCAUDAL DIMENSION AND ANTERIOR POSTERIOR DIMENSION OF APPROXIMATELY 26.3 MM. DIAGNOSTIC CONSIDERATIONS INCLUDE PRIMARILY FOR MACROADENOMA BUT ADDITIONAL DIAGNOSTIC CONSIDERATIONS INCLUDING CRANIOPHARYNGIOMA CANNOT BE EXCLUDED. THERE IS ALSO INCIDENTALLY MILDLY DILATED BILATERAL LATERAL VENTRICLES.



## COMPRESSIVE OPTIC NEUROPATHY

- Results from compression of the optic nerve within orbit, at the orbital apex, chiasm-secondary to:
  - Space occupying orbital lesions, including tumor masses
  - Infiltrated extraocular muscles (Graves' ophthalmopathy) in thyroid disease (most common)
- Unilateral with orbital masses, can be bilateral in Graves' disease
- Presents with slowly progressive, variable vision loss; variable proptosis and motility restriction

## COMPRESSIVE OPTIC NEUROPATHY

- Optic nerve may be initially hyperemic with retinal edema, tortuous vessels, and associated hemorrhages; with prolonged compression, may see pallor and optic disc collateral vessels
- Visual fields consistent with papilledema in early stages, ischemic optic neuropathy/ glaucoma in later stages
- Increased concentric 'cupping' can occur
  - Compression causes pallor; glaucoma causes notching
- Management involves orbital imaging and serum thyroid profile if Graves' suspected

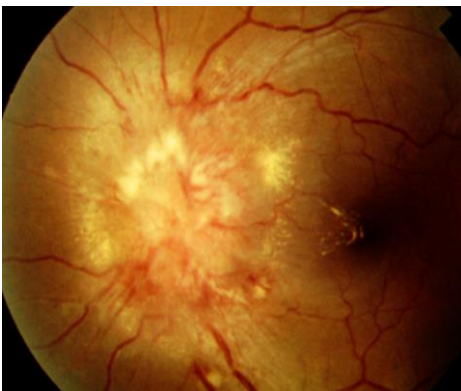## ODE TO A CUPPED DISC

Oh, to have a cupped disc pink.  
That my friend hath a glaucomatous stink.  
But to have a cupped disc pale,  
Call this glaucoma and you shall fail.  
Disc and field damage that is one-sided  
Simply cannot be abided.  
It might be trauma, infarct or meningioma.  
But if the rim is cut always remember,  
Nothing notches a nerve like glaucoma

Joseph Sowka, OD

## 42 YOF

- Sudden painless loss of vision OS x 1 week
  - getting worse, not getting better
  - began as dimming, then rapidly dropped off
- BVA: 20/20 OD; 20/400 OS
- PERRL (+) RAPD OS (mild)
- Conf. Fields: FTFC peripherally OD, OS
- Amsler: Central/cecocentral scotoma OS
- SLE: normal OU
- IOP: 18 mm Hg OD, 19 mm Hg OS



## 42 YOF

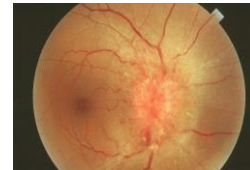
- No known HIV risk
- Recent illness: Severe flu with malaise, fever, and lymphadenopathy 4 weeks antecedent.
- No tick bites or rashes
- Exposure to cats
- Serology:
  - FTA-ABS/RPR; HIV, Lyme, toxoplasmosis, toxocariasis, PPD: Negative
  - Bartonella henselae titers: positive
- Dx: Cat scratch neuroretinitis

## INFECTIOUS OPTIC NEUROPATHY

- **Syphilis**
  - Retrobulbar, papillopathy, neuroretinitis, perineuritis
  - Retrobulbar, bulbar: severe vision reduction
  - Perineuritis has normal vision, MRI optic sheath enhancement
- **Lyme - mimics syphilitic optic neuropathy**
  - Bite of mammalian deer tick- can cross react with syphilis
- **Toxoplasmosis, HIV/AIDS, CMV**
  - Destructive to vision
- **Neuroretinitis**
  - Typically benign lymphoreticulosis (cat scratch disease)

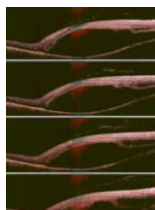
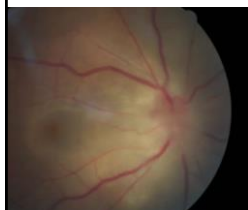
## NEURORETINITIS

- **Mild RAPD compared to vision loss**
  - Vision loss more retinal than optic nerve
- **Serous macular RD**
  - OCT shows subretinal fluid between disc and macula in cases with disc edema only
- **Macular star late finding**



## 62 YOF

- 'Strep throat'
- CF @ 8' OD, 20/25 OS – antibiotics x 1 day
- RAPD OD
- Black spot and blurry vision 3 days



## NEURORETINITIS

- **Many potential etiologies**
  - Toxoplasmosis, toxocariasis, measles, syphilis, Lyme disease, herpes simplex and zoster, mumps, tuberculosis, malignant hypertension, ischemic optic neuropathy, and leptospirosis, *bartonella* (most common). Fleas are vectors, thus no need for actual scratch.
- **Prognosis for visual recovery excellent, especially if the cause is cat scratch disease.**
  - Most patients will have a return to normal or near normal vision without
  - Antimicrobial therapy may be used to hasten recovery.
    - Rifampin, ciprofloxacin, doxycycline, sulfamethoxazole; doxycycline 100 mg PO BID for one month. Intravitreal injection of Avastin<sup>TM</sup> (bevacizumab) has been shown to improve both visual acuity as well as decrease macular edema. However, the overall good prognosis of neuroretinitis may not justify this treatment, especially since this information comes from case reports and not controlled clinical trials
  - While antibiotics are frequently used for cat scratch disease neuroretinitis, there are no controlled clinical trials that indicate a better clinical outcome from this therapy. The same can be said for the use of oral steroids and intravitreal anti-angiogenic medications.

## ODE TO AN INFECTED NERVE

When the vision is poor and the APD mild,

It's often the bite of something wild.

If the disc is swollen and macular swelling great,

Its neuroretinitis and the star comes late.

Syphilis and Lyme are alike,

and can cause similar titres to spike.

One is transmitted sexually and the other not,

Unless the patient is weirder than you thought.

Joseph Sowka, OD

## 34 YOF

- ◎ Patient referred by PCP for complete ocular evaluation
- ◎ CC: sudden onset "foggy" vision and pain OS X 2 days
  - retrobulbar pain; exacerbated with eye movement
- ◎ Medical Hx:
  - Hodgkin's lymphoma X 2 years, currently in remission
  - most recent Gallium scan negative
  - (-) meds , (-) allergies

**34 YOF**

**BVA:** OD 20/15, OS 20/25 (PHNI)

**Pupils: (+) RAPD OS**

**Confrontation Fields**

- full OD
- dense constriction OS

**Color Vision (Ishihara):**

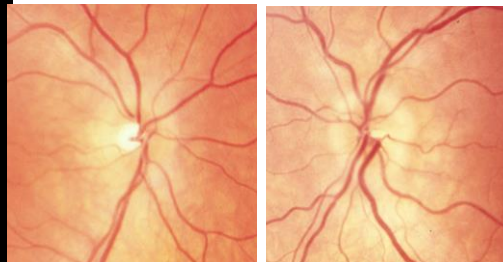
- OD 8/8
- OS 1/8

**Biomicroscopy:**

- all external structures normal OD & OS

**Tonometry (Goldmann):**

- 14 mm Hg OD
- 14 mm Hg OS



**Presumptive diagnosis?**

**34 YOF**

- **Presumptive diagnosis:** Left optic neuritis
- **Differential diagnosis:** demyelinating, infiltrative, infectious optic neuropathy
- **Plans:** Automated perimetry - patient scheduled to return in 16 hours
- **Refer for neuroimaging and hematological studies**

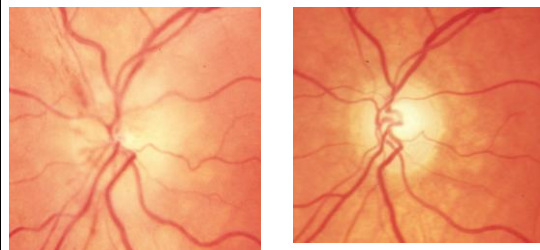
**34 YOF**

- **Patient returns for perimetry - acuity now NLP OS Patient immediately referred, admitted for evaluation:**

- **MRI** (with contrast, brain & optic nerves):
  - no UBO's identified, no "meningeal enhancement"
- **HEMATOLOGY:**
  - **ESR** = 37 mm/hr
  - **ANA** (-)
  - **D/S DNA** initially (+), then (-) on repeat testing
- **CSF STUDIES:**
  - normal ICP (O.P. = 180 mm H<sub>2</sub>O)
  - normal cell count, no evidence of lymphoma

**34 YOF**

- **Patient admitted to hospital for testing and therapy- I.V. corticosteroids**
  - 250 mg methylprednisone sodium succinate QID
  - therapy was poorly tolerated; discontinued after 3 days- no oral steroids given
- **Patient discharged after four days**
- **Subsequent evaluations (2 weeks, 4 weeks, 3 months, 6 months) demonstrated no improvement in visual acuity**
- **Presumptive Etiology:**
  - Infiltrative Optic Neuropathy Secondary to Lymphoma



2 weeks

4 weeks

## INFILTRATIVE OPTIC NEUROPATHY

Disorders associated with infiltrative neuropathy:

- Sarcoidosis
- Systemic lupus erythematosus
- Leukemia
- Lymphoma
- Metastatic cancer
- Primary optic nerve tumors

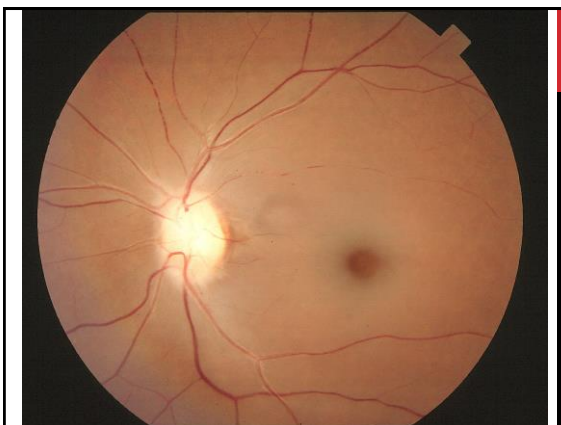
## INFILTRATIVE OPTIC NEUROPATHY: MEDICAL MANAGEMENT

- Neuroimaging (MRI w/ & w/o gad preferred)
- LP (if neuroimaging is negative)
- Hematology and serology:
  - ANA, ACE, D/S DNA
  - histologic analysis for leukemic and lymphocytic cells
  - consider also FTA-Abs & RPR, ELISA-HIV
- Evaluation by GP

## NOW FOR SOME RETINA...

## CASE: I (DON'T) FEEL GOOD!

- 66 year old Black male
- CC: sudden, painless blurring OS x 3 days
- No previous eye or medical care
- Wants glasses to clear vision
- BVA OD 20/30, OS HM
- Pupils: ERRL (+) RAPD OS
- Good appetite, poor diet

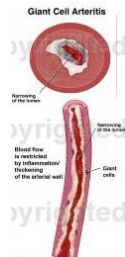


## CENTRAL RETINAL ARTERY OCCLUSION (CRAO)

- Painless, sudden loss of vision
  - < 20/400 in most cases
- Retinal edema and white fundus – hypoperfusion
  - Cherry red spot
- 60's and above
- Early and late appearances
  - Initially normal fundus
  - Optic atrophy with attenuated vessels

## CRAO: ETIOLOGY

- Emboli from heart or carotid lodging at lamina
- Intraluminal thrombosis
- Dissecting aneurysm
- Vasospasm
- Arteriolar necrosis
- **GIANT CELL ARTERITIS!**



## CRAO: TREATMENT ?

- Paracentesis
- Carbogen
- Digital massage
- Hyperventilation
- Urokinase/streptokinase
- 1-24 hr window of opportunity
- Does anything work?



## CRAO: SYSTEMIC CONSIDERATIONS

### Atherosclerosis

Carotid artery disease

### GCA

Antiphospholipids ABS

Infectious endocarditis

Vasospastic disease

Cardiac arrhythmia

Clotting factor abnormalities

### Hypertension

### Diabetes

Cardiac valve disease

Cardiovascular disease

Hyperlipidemia

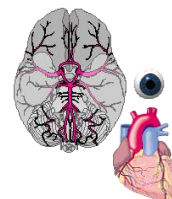
Disc drusen

Mural thrombosis

Hyperviscosity syndromes

## CRAO: COMPLICATIONS

- CVA
- MI
  - Main cause of death
  - 9 yr mortality 56%
- NVG
- OIS
- Fellow eye involvement if GCA cause



## CRAO: MANAGEMENT

- STAT ESR and CRP for GCA
- Cardiology/ internal medicine referral
- Monitor in 3-6 mos for neovascularization
  - How common is neo?

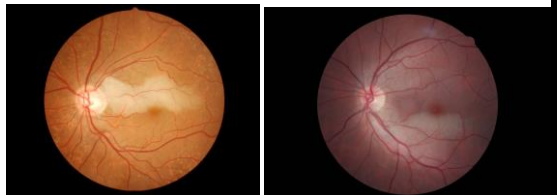

## JAMES' OUTCOME

- Referred for medical care
- Diagnosed with hypertension, NIDDM, hypercholesterolemia
- Returns for ocular follow up 3 months later
  - "I'm scared"
- Several toes amputated from diabetes
- Passed away from MI within year

## BRAO; CILIORETINAL AO

- BRAO nearly always embolic
- Greater risk of cardiac mortality
- Cilioretinal AO- branch of PCA- high risk of GCA



## Guidelines



- Any patient with suspected TIA or those with acute retinal ischemia should be evaluated urgently in order to identify those at high risk of immediate cerebral infarction and cardiac ischemia

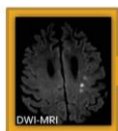Guidelines for the prevention of stroke in patients with stroke or transient ischemic attack: a guideline for healthcare professionals from the American Heart Association/American Stroke Association. *Stroke* 2013; 44: 527-576

Adapted from Drs. Nancy Newman and Biousse; 2015

## All Patients with Acute Retinal Arterial Ischemia



- MUST have immediate brain imaging
  - Brain MRI with DWI >>> Head CT
- Including patients with transient visual loss (presumed of vascular origin)

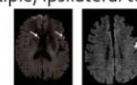


Presence of cerebral ischemia portends higher risk of stroke

Adapted from Drs. Nancy Newman and Biousse; 2015

## Concurrent Acute Brain Infarcts in Patients with Monocular Visual Loss

- ¼ with acute retinal ischemia had acute brain infarction (anywhere) on brain DWI-MRI
  - Infarctions often small, multiple, ipsilateral to retinal ischemia, asymptomatic
- DWI-MRI abnormal in:
  - 33% with CRAO/BRAO vs 18% with TVL
  - 28 % with embolic vs 8% non-embolic retinal ischemia



Adapted from Drs. Nancy Newman and Biousse; 2015

## Study #2

Co-occurrence of Acute Retinal Artery Occlusion and Acute Ischemic Stroke: Diffusion-Weighted Magnetic Resonance Imaging Study

JUNWON LEE\*, SEUNG WOO KIM\*, SUNG CHUL LEE, OH WOONG KWON, YOUNG DAE KIM, AND SUK HO RYEON

Am J Ophthalmol 2014; 157: 1231-1238

Adapted from Drs. Nancy Newman and Biousse; 2015

## Co-occurrence of acute retinal artery occlusion and acute ischemic stroke: Diffusion-weighted magnetic resonance imaging study

- 33 patients with CRAO (18) and BRAO (15)
- Evaluated similarly to acute stroke patients (DWI)
- ¼ with acute retinal ischemia had acute brain infarction (anywhere) on brain DWI-MRI
  - 5/18 CRAO; 3/15 BRAO
  - Infarctions often small, multiple, ipsilateral to retinal ischemia, may be asymptomatic
  - Abnormal DWI-MRI strongly correlated with major cause of stroke (even when neurologically asymptomatic)

Adapted from Drs. Nancy Newman and Biousse; 2015



## DWI in Acute Retinal TIA/Ischemia

- DWI-MRI identifies subgroup of patients at very high risk of major stroke
- DWI-MRI needs to be performed within 24/48 hours of visual loss to allow for effective prevention of recurrent stroke

Adapted from Drs. Nancy Newman and Biousse; 2015

## Tell the patient:

- "Go to the Emergency Department"



- "Tell them you had a retinal stroke"
- Do not send these patients to their PCP, cardiologist, neurologist, neuro-ophthalmologist
- Do not try to obtain the workup yourself

Adapted from Drs. Nancy Newman and Biousse; 2015

## ODE TO AN ARTERY OCCLUSION

When the vision is poor and the fundus is pale,  
A branch or laminar emboli has caused the fail.

Heroic measures are rarely helpful,

And vision return is doubtful.

In an Oldie, always remember giant cell it may be.

Hurry and get an ESR and CRP.

The retina is infarcted and dead,

So neo you should not dread.

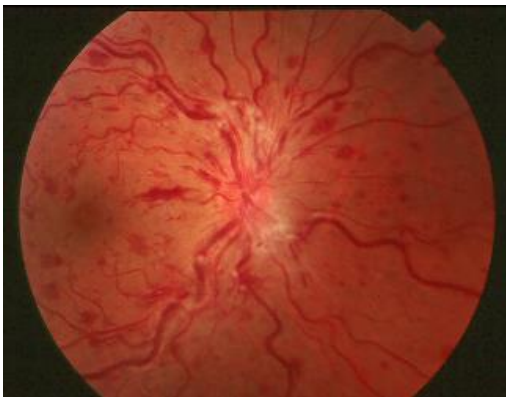But here is where you must not choke,

Send them to the ER because they are having a stroke

Joseph Sowka, OD

## THE CASE OF THE COLORED FLASHING LIGHTS

- 45 YOHF presented with colored "map-like" phosphenes and small black flashing spots OD x two weeks
- Noted that she had to "look between the lights" to see out of her right eye.
- 20/20 OD, OS
- Medical history was unremarkable except for treated migraines
- Lost 1 pregnancy



So,  
What's your diagnosis?



Management...?






## CASE CONTINUED

- She returned four days later complaining of decreased vision in the right eye, which had reduced to counting fingers at ten feet.
  - Macular edema, more extensive hemorrhaging, cotton wool spots, disc edema and dilated vessels
- Underwent IV Kenalog injections and showed improved vision of 20/70 OD during follow up examinations.
  - Released by retinal specialist
  - No medical evaluation

Now  
What?



Are there any tests that you would like to order?

## CRVO: SYSTEMIC CONSIDERATIONS

*Hypertension*

*Hyperviscosity*

CV disease

Sickle

Polycythemia

Hyperlipidemia

*Autoimmune factors*

*Homocysteine*

*Diabetes*

*Syphilis*

Cardiovascular disease

Leukemia

Carotid artery disease

Sarcoid

Clotting abnormalities

## TREATMENT & MANAGEMENT

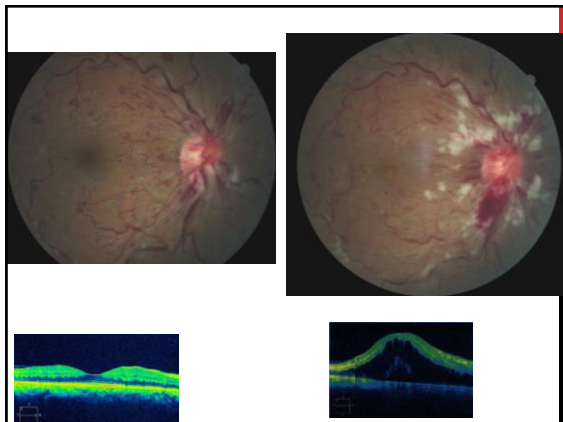
- Referred blood work through PCP
  - DM, HTN, hypercoag, ANA, antiphospholipid antibodies, anticardiolipin, PT, PTT, ESR, CBC with diff
- Elevated erythrocyte sedimentation rate
- Mildly elevated cholesterol level.
- Elevated anti-cardiolipin IgM antibodies
  - Suggestive of antiphospholipid antibody syndrome
  - She was recommended for long term anti-coagulant therapy to prevent future thrombotic events, but patient never followed through.

## CASE CONTINUED

- Seven months later the patient returned with the same signs and symptoms in her right eye.
- At this time, the vision was markedly more decreased with more evidence of ischemia
  - CF @ 6'
- She was referred to a hematologist
- Now on anti-coagulation therapy

## CENTRAL RETINAL VEIN OCCLUSION

- Thrombotic/atherosclerotic phenomenon
- Properties of blood and vein act in concert
- Vascular flow and vessel wall abnormalities
- Problem at lamina
  - Turbulent flow
  - Decreased luminal pressure
  - Thrombus
- Perfused; non-perfused; indeterminant
- Evolving condition



## MANAGEMENT-CRVO

- **Standard Care vs. Corticosteroid for Retinal Vein Occlusion (SCORE)**
  - 1-mg of IV triamcinolone should be considered for one to two years to improve vision loss secondary to macular edema following a CRVO.
- **CRUISE Results**
  - Demonstrated efficacy for Lucentis treatment

## PRIMARY ANTIPHOSPHOLIPID ANTIBODY SYNDROME

- **Thrombotic disorder**
- **Secondary antiphospholipid syndrome**
  - Associated several autoimmune diseases but most often systemic lupus erythematosus
- **Primary antiphospholipid syndrome is not associated with further systemic disease**
- **Recurrent vascular thrombosis, pregnancy loss and positive anticardiolipin or lupus anticoagulant are all characteristics of this disorder**

## PRIMARY ANTIPHOSPHOLIPID ANTIBODY SYNDROME

- **The clinical criteria**
  - One or more vascular thrombotic episodes of venous, arterial or small vessel thrombosis in any organ or tissue or spontaneous abortion.
- **Laboratory testing must show persistently elevated anticardiolipin antibodies, IgG and/or IgM or lupus anticoagulant (inhibits the conversion of prothrombin to thrombin) at least six weeks apart**

## PRIMARY ANTIPHOSPHOLIPID ANTIBODY SYNDROME

- **Phospholipids are identified by the body as "foreign."**
  - The antiphospholipid antibodies are produced against the "foreign" antigen.
- **The antibodies appear to react with the cell membranes causing irritation or stimulation, thus disrupting the coagulation cascade**
- **This disruption leads to abnormal blood clotting and inhibits normal phospholipid binding.**

## PRIMARY ANTIPHOSPHOLIPID ANTIBODY SYNDROME

- **This abnormal or inhibition of proper phospholipid binding leads to a hypercoagulable state thus causing thrombosis.**
- **Propensity of clot formation is within the venous and arterial portions of the vascular tree, especially targeting the retinal vessels and placenta**

## MORAL OF THE STORY

**Just because you refer  
somebody out doesn't  
mean that everything will  
be addressed**

## ODE TO A CENTRAL VEIN OCCLUSION

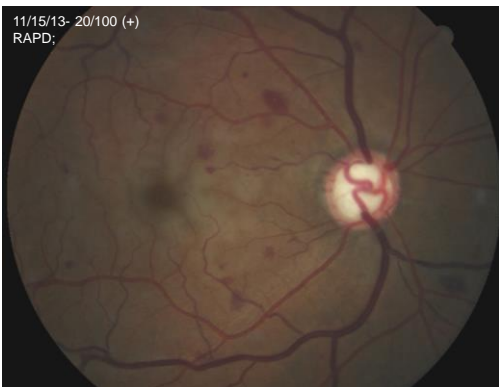When the veins are tortuous and dilated,  
A laminar thrombus has violated.  
With hemorrhages in all four quads,  
Macular edema reduces vision at odds.  
A pupil defect and poor vision,  
Mark the division,  
Between ischemia and not.  
Laser doesn't help edema,  
And shouldn't be in the schema.  
Steroids and anti-VEGF you can inject,  
So vision won't be wrecked.  
Remember neo forms front not back  
PRP is needed to prevent the eye from seeing black

**Ok, now that  
we have  
warmed up...  
Let's see if we  
can figure this  
one out.**

## 50 YOIF

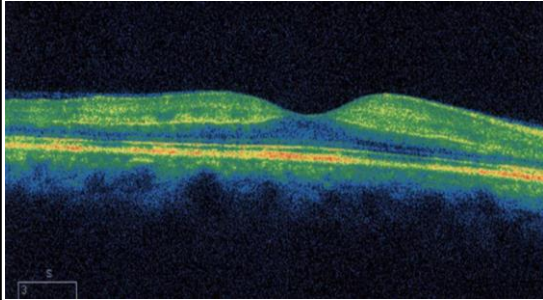
- POAG OU x 10 years- medically controlled
  - PGA, beta blocker
- Hx CVA at age 17
  - No cause found
- N/S x 1 year
- Presents with sudden onset vision loss OD (6 hrs)
  - IOP 22 mm OU; using PGA, not using beta blocker
- 20/100 OD; 20/20 OS; 3+ RAPD OD
  - Never present before

11/15/13- 20/100 (+)  
RAPD;



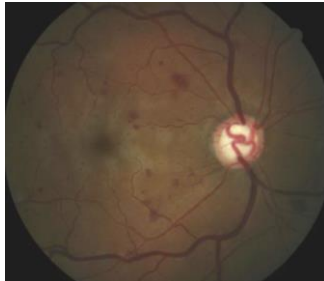So,  
What are your  
thoughts?



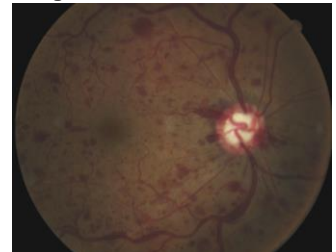


- **Digital massage and combigan given**
  - No improvement
- **Recommend retinal consult for angiogram- pt initially declines**
  - Pt ultimately sees retinal specialist next day
- **Angiogram *normal*.**
  - Normal arterial filling 'somewhat delayed' venous filling. No evidence of edema or ischemia- pt released

- **Pt returns 6 days later**
- **Some visual improvement**
  - 20/60 OD
  - RAPD now grade 2
  - IOP 12 mm OU
  - Ischemia
- **f/u 1 mos**



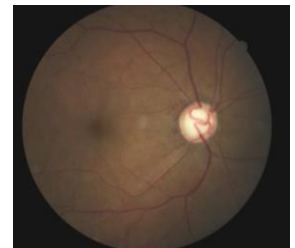- **Pt returns 3 weeks later**
- **Vision improved to 20/30**
- **RAPD diminished to grade 1**



So,  
What are your  
thoughts?



- **CRVO? CRAO? Variant?**
- **Reappointed for 1 month**
- **Pt returns as scheduled- vision improved**
  - 20/25+
  - RAPD disappeared

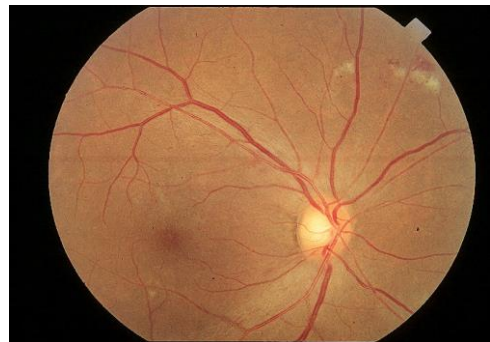
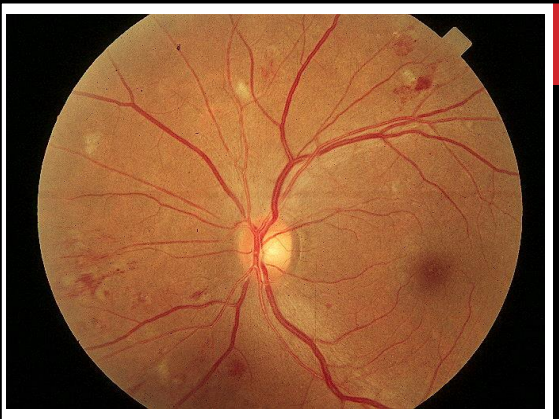


## QUESTIONS

- Artery or vein occlusion?
- Why OCT and FANG normal?
- How does RAPD form and disappear over 2 months?

## THE MEDICINE MAKES ME SICK

- 52 YOWF
- Medical history: hypertension x 10 years;  
NIDDM x 2 yrs
  - Medicines unknown
  - Poorly controlled
  - Pt non-compliant
  - "God will take care of me"
- BP: 157/109 RAS



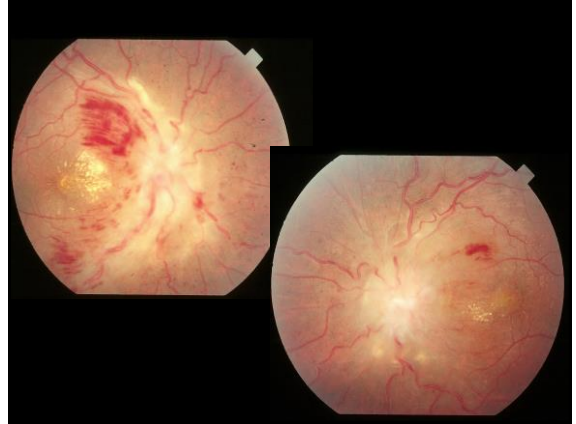
**So, What do you think?**

## HYPERTENSIVE RETINOPATHY

- Arteriolosclerotic vessel changes
  - Some classification schemes include vessel changes in hypertensive retinopathy and others don't
- Elschnig's spots – subtle choroidal infarcts
- CWS
- Flame shaped hemorrhages
- Macular edema (rare)
- Macular star/ ring of exudates
- Disc edema

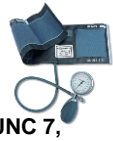## NOW A TWIST

- 47 YOBM
- Obese
  - 400 lbs (and that's being kind!)
- Headaches x 3 months
- Vision reduction x 2 months
  - 20/50 OU
- BP: 212/155 RAS



So, What do you think?

## BLOOD PRESSURE



- “Normal” blood pressure:  
≤ 120/80 (systolic / diastolic) JNC 7, 2003
- Hypertension is defined as any elevation of blood pressure above the norm, as measured by sphygmomanometry on two separate occasions

Prehypertension: 120-139 (S) and/or 80-89 (D)

Stage 1 hypertension: 140-159 and/or 90-99

Stage 2 hypertension (severe): ≥160 and/or ≥100

## HYPERTENSIVE CRISES

**Hypertensive EMERGENCIES**  
&  
**Hypertensive URGENCIES**

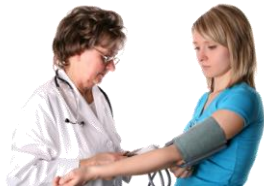

## HYPERTENSIVE EMERGENCY

- **Severe Hypertension + End-Organ Damage**
  - Examples of end-organ damage... *hypertensive encephalopathy, intracerebral hemorrhage, acute myocardial infarction, left ventricular failure with pulmonary edema, acute coronary syndrome, dissecting aortic aneurysm, or eclampsia*
- **Hypertensive EMERGENCIES require immediate BP reduction (not necessarily to normal ranges) to prevent or limit organ damage.**
  - Patients with hypertensive emergencies are often admitted through the ER for aggressive treatment.

## HYPERTENSIVE URGENCY

- Severe Hypertension + **NO** End-Organ Damage
  - Typically identified during **routine** evaluation
  - Usually represents chronic hypertension, nonadherence to drug therapy or inadequate treatment by the PCP.



## HYPERTENSIVE URGENCY

- **DOES NOT** warrant aggressive BP reduction, as rapid reduction of BP may be associated with significant MORBIDITY:
  - Causes a rightward shift in the pressure/flow autoregulatory curve in critical arterial beds (cerebral, coronary, renal).
  - Can result in marked reduction in perfusion, causing ischemia and infarction; BP must be reduced in a SLOW and CONTROLLED fashion.
  - Patients with hypertensive urgencies are usually treated with oral medications and followed over several days to weeks to evaluate their response to therapy.

## INDUCTION OF ADVERSE EVENTS SECONDARY TO TOPICAL PHENYLEPHRINE

- Regarding 2.5% phenylephrine (PE), numerous reports suggest there is little concern over adverse responses:
  - *Jennings et al (1986)* – 252 patients (3 – 92 years); no significant changes in systolic or diastolic BP in patients dilated with 2.5% PE.
  - *Malhotra et al (1998)* – 54 consecutive patients undergoing cataract extraction; no sustained changes in BP or heart rate after 2.5% PE.
  - *Lam et al (2003)* – 217 consecutive patients undergoing phacoemulsification; no untoward cardiovascular effects with 2.5% PE.



## INDUCTION OF ADVERSE EVENTS SECONDARY TO TOPICAL PHENYLEPHRINE

- Approximately 41 cases involving adverse systemic reactions to 10% phenylephrine have been reported...
  - 15 patients suffered myocardial infarction after instillation of 10% PE, of which 11 resulted in fatality; these individuals had an average age of 71 years, and nine had a known history of cardiac disease.



- Pharmacologic dilation can help to identify target end-organ damage, particularly hypertensive encephalopathy (Stage 4 hypertensive retinopathy) and intracerebral hemorrhage (Terson's syndrome). Therefore, in patients with significantly elevated BP, dilated funduscopy is of PARAMOUNT importance, but...

**IS THERE A SUBSTANTIAL RISK TO THE PATIENT??**



## CONCLUSIONS & RECOMMENDATIONS

- Based on data submitted to the National Registry of Drug-Induced Ocular Side Effects:
  - 2.5% PE is recommended for routine pharmacologic dilation.
  - 10% PE should be avoided in the elderly, infants, and patients with cardiac disease, idiopathic orthostatic hypotension, hypertension, aneurysms, Type 2 diabetes, and advanced arteriosclerosis.
  - 10% PE should also be avoided in patients using MAO inhibitors, tricyclic antidepressants, reserpine, guanethidine, or methyl dopa.



# ARE THERE ANY QUESTIONS?



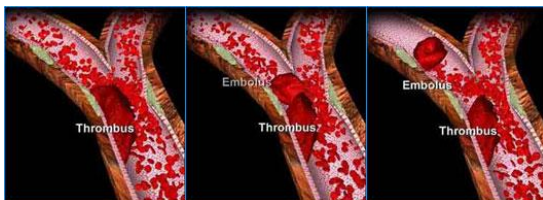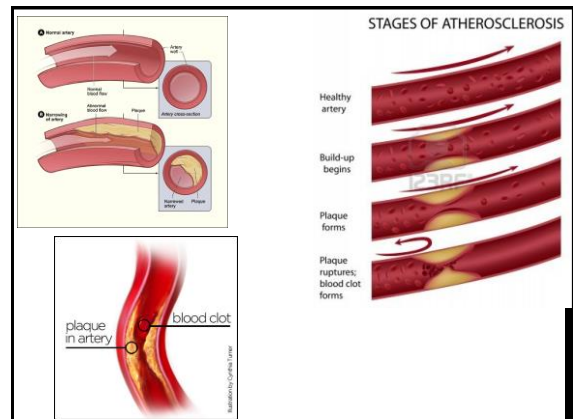
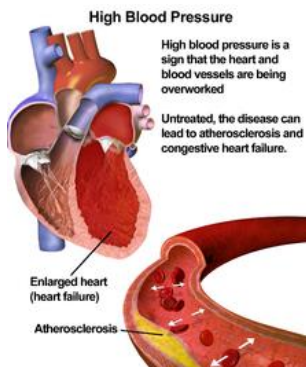
## IMPENDING STROKE

### AF and TIA

- hemiparesis, hemisensory loss, hemifacial weakness of upper motor neuron distribution, amaurosis fugax, and aphasia
  - < 1 hr; no changes on neuroimaging
  - AF: light-induced, gaze-induced

### Atherosclerosis with subsequent visible retinal emboli formation from hypertension

- Cholesterol → fatty streak → atheroma → ulceration → thrombus → plaques → emboli



## VISIBLE RETINAL EMBOLI

### Fibrin/platelet aggregate (Fisher plaque-carotid in origin, also walls of arteries and valves of heart)

- Dull gray or white
- Readily migrate through vascular system producing symptoms (AF)

### Hollenhorst- cholesterol (carotid in origin)

- Refractile, glistening, yellow
- Most common (87%) of all emboli
- Typically do not occlude artery
- Malleable and allows for blood to pass though the artery may appear totally blocked
- Will readily break up and move distally, so will not be seen typically in patients complaining of AF
- common cause of AF

### Calcific (cardiac)

- Dull white and non-refractile
- Usually from valvular calcification
- Most likely to cause artery occlusion and stroke

## TIA

### ■ Anterior circulation

- internal carotid, middle cerebral, anterior cerebral arteries, and their tributaries.
- Receives 80% of the cerebral blood flow and accounts for 80% of transient ischemic attacks and strokes.
- Amaurosis fugax indicates an abnormality in the ophthalmic branch of the internal carotid artery distal to the bifurcation
  - CRA, BRA

## TIA/ AF

### ■ Emboli-forming conditions (other than HTN)

- Rheumatic heart disease
- Prosthetic heart valves
- Bacterial endocarditis
- Indwelling catheters
- Rhythm disturbance - Mitral valve prolapse

## TIA/AF

### ■ GCA

- Thrombus, not emboli

### ■ Vasospastic

- Non-embolic arterial narrowing
- Vasospastic substance (Cocaine) use
- Migraine?

### ■ Hematological

- Polycythemia (Too much hemoglobin)
- Sickle cell (#1 hematological cause of transient vision loss)
- Anemia (Too little hemoglobin)
- Hypercoagulability states
- Anti-phospholipid antibody syndrome

## TIA

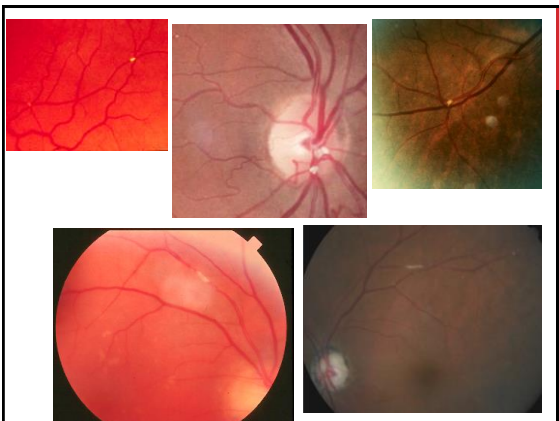
### ■ Possibility of a subsequent CVA

### ■ TIA also indicates widespread vascular disease putting patients at risk of myocardial infarction and cardiac death

### ■ Patients with amaurosis fugax as only manifestation of TIA are at lesser risk than pts. with hemispheric TIA

- Risk of arterial occlusion (with permanent vision loss), CVA, and MI.

### ■ Risk of future events for TIA dictated by cause and degree or carotid stenosis



**THANK YOU FOR YOUR ATTENTION.  
ALWAYS REMEMBER TO RECYCLE AND  
PROTECT THE PLANET THAT WE WILL  
ULTIMATELY LEAVE TO KEITH RICHARDS**

