

My Favorite Cases

Paul C. Ajamian OD
Diplomate, American Board of Optometry

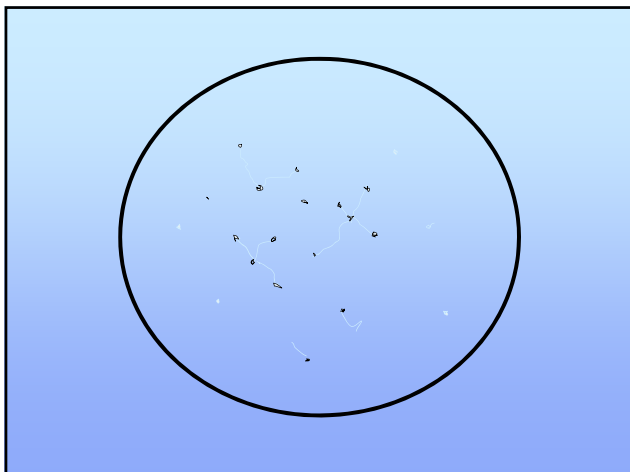
Disclosures

- No financial disclosures, no industry relationships

First, a few rules to live by...

1. Be observant and curious
2. Never panic before you examine
3. Don't be afraid to tackle new things
4. Always explain VA loss less than 20/20 or have a plan to do so

Rule 1: Be Observant!



Rule 2: Don't Panic!

- ❖ **Even if others before you missed the dx doesn't mean you will**
- ❖ **Calmly assess the eye, one medical finding at a time**

Let's just get it out of the office!

Rule 3: Don't Be Afraid to Tackle New Things

- **Glaucoma is still an area of untapped potential for optometrists!**
- **Lacrimal procedures**
- **If you are referring, always ask "what are they going to do that I cannot"**

Rule 4: Explain VA Not 20/20

- **54 WF -11.00 her entire life**
- **Now -12.00, VA 20/50 best OU**
- **Sent in for early cataracts but told that “didn’t explain” the vision loss, needs second opinion**

Milky NS

- Continues to stump MDs and ODs alike
- Myopic shift
- Looks innocuous as if it can’t cause the VA that is noted
- Bowing of beam

PA1

Rule 5: Don’t Be Distracted by Red Herrings!

- **Always get the big picture and look beyond what patient is telling you**

The Devil is in the Diagnosis

Slide 11

PA1

Paul Ajamian, 2/19/2018

Play Ball!

- 76 yo Braves Shortstop
- Best VA 20/60 ou from dense NS
- Sent in for “same day” cataract evaluation

- IOP 19/20
- Significant cupping, inferior arcuate defects

Moral of the Story

- NEVER NEVER miss a cupped disc!
- Patients can have more than one problem with their eye!

“Every Patient You Examine Has Glaucoma Until Proven Otherwise”

Have we gotten any better over the years at diagnosing OAG?



Harry Quigley, SECO 2014

- Many undiagnosed OAG cases found at Johns Hopkins medical clinic
- Many of these had an eye exam by optometrist or ophthalmologist within the last year
- More of the undiagnosed cases had normal IOP

And beyond that...

- Because we are no longer forced to draw discs, we are losing our skills at assessing cup to disc ratio and nuances of rim asymmetry/thinning

OAG frequently occurs at normal IOP: get over it !

- Population surveys show 50% of OAG patients rarely have IOP >21
- The risk factor is not "elevated" IOP
- It's the level of IOP that matters
- The higher the IOP, the greater the risk whatever the baseline IOP is
- *Dump the magic number*

Wilson MR. The myth of "21". J Glaucoma 1997;6:75-7.

Don't separate "Low Tension" and "High Tension"

- Disc and field findings are very similar
- Treatment is the same: target IOP concept
- MRIs on "low tension" are worthless and scare patients needlessly

Schulzer M, Drance SM, Carter CJ, Brooks DE, Douglas GR, Lau W. Biostatistical evidence for two distinct chronic open angle glaucoma populations. Br J Ophthalmol. 1990;74:196-200.

Greenfield DS, Siatkowski RM, Glaser JS, Schatz NJ, Parrish RK. The cupped disc. Who needs neuroimaging? Ophthalmol 1998;105:1866-74.

- Lee Study: less than 40% of MD's (non glaucoma specialists) examined or documented optic nerve head within two years of last exam
- While photos and drawings are the standard of care, less than 30% of charts audited in study had one or the other performed
- His conclusion: "We need to do a better job of examining the nerve, drawing the nerve and doing more fields in eyes with suspicious discs"

Paul P. Lee, MD JD Ophthalmology Times May 2005

- 19 WM
- Helping Dad run some wires in the attic
- Live wire strikes him in the right eye!



- Mother calls their family eye doctor because son is in so much pain
- They are told by phone "we better send you to Omni right away, "that's probably not something we can handle here"

Management

- Antibiotic q2 h after debriding the loose epithelium
- Topical NSAID to take the edge off the pain
- He returns to his OD the next day....almost totally healed!

67 WM

- s/p Symphony Toric IOL OS 9/26/16
- Day 1: 20/20 J1
- Day 14: Comes in for second eye surgery OS: still 20/20 J1

Your tentative diagnosis?

- Episcleritis?
- Scleritis?
- Rebound iritis?

More history?

- Nothing unusual
- Oh, maybe I felt something Sunday working in the yard
- Oh, wait, I was walking the dog and ducked through some bushes and a branch hit my eye!

Lessons learned

- Have to be curious and dig deep
- Episcleritis is rare, scleritis is rarer
- Conjunctival abrasions are common and even more commonly misdiagnosed!
- Antibiotic, not steroid therapy

The Case of the Running Eye



- 41 WF
- Breast cancer survivor
- Worried about itching and “tearing” OS > OD, worse when “out of contacts”

Pearl

- Always ask about tearing...”do the tears run down your face?”

Yes Tears Down Cheeks? No

↓ ↓

Check for punctal apposition & patency, blockage of canaliculus

dry eye workup


True epiphora

- examine punctal openings (size and apposition to globe), then dilate/irrigate to determine site of blockage

Irrigating Cannulas/Dilators

- Shahinian Lacrimal Cannula, straight (bullet tip 23 ga)


Amblersurgical.com or
BauschInstruments.com or
Katena.com



The diagram shows a cross-section of a bullet-tipped cannula with a central lumen. The photograph shows the physical device, which is a thin metal tube with a rounded, bullet-shaped tip and a small circular opening at the base of the tip.

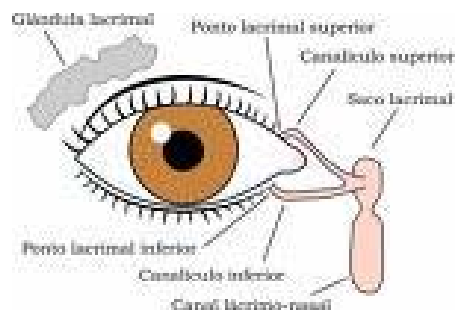
Burnstine cannula

- Combination dilator/irrigator
- Katena.com



The photograph shows a combination dilator/irrigator device. It consists of a long, thin needle-like tip attached to a larger, cylindrical handle with a textured grip. A circular inset provides a magnified view of the tip, showing a small opening at the very end.

Irrigation



Take Home Pearl

- Always ask about tearing...“do the tears run down your face?”
- Think about adding lacrimal procedures to your practice!

In a nutshell.....

- Be a good observer
- Stay on the cutting edge
- Give yourself a chance by seeing patients first
- Know when to refer and to whom

Conquer Your Fears

22 HM with “swollen lid”

Quick Facts

- MG may mimic any EOM palsy
- 75% of pts have ocular symptoms initially
- This is a neurological disease
- Treatment with anticholinesterase agents may not be effective>>>switch to steroids
- Consider thymus gland

The Case of the Hurting Face

- ⊙ 73 BF
- ⊙ 1 week hx of severe mucopurulent drainage OS and a red eye
- ⊙ Began noting “raw, irritated” skin above and below eye with itching

- Was applying frequent hot soaks to area around OS
- Awoke the morning we saw her with swelling below RLL

Your diagnosis?



Atopic Dermatitis

- Think of it as a form of eczema triggered by a variety of irritants
 - Soaps, harsh chemicals, heat, stress, foods, and certain infections such as
- Staph Aureus: a frequent cause of this condition with skin response in periorbital region

Management

- Ofloxacin drops OS QID
- Tobradex ointment for eczema
- Benadryl OTC 25mg tabs QID
- Total resolution 4 days later with photos to prove it!