OCT and OCT Angiography in Glaucoma

Greg Caldwell, OD, FAAO
Optometric Education Consultants

August 29, 20/20

Disclosure Statement
(next slide)

Disclosures- Greg Caldwell, OD, FAAO

- Will mention many products, instruments and companies during our discussion
  - I don't have any financial interest in any of these products, instruments or companies
- Pennsylvania Optometric Association –President 2010
  - POA Board of Directors 2006-2011
- American Optometric Association, Trustee 2013-2016
- I never used or will use my volunteer positions to further my lecturing career
- Lectured for: Aerie, Alcon, Allergan, BioTissue, OptoVue
- Advisory Board: Allergan, Maculogix, Sight Sciences, Sun, Takeda
- Envolve: PA Medical Director, Credential Committee
- Optometric Education Consultants- Scottsdale, St. Paul, Quebec City, Nashville, and Orlando/Disney OCT Users meeting; Owner

Optometric Education Consultants

OCT Anterior Segment Applications in Glaucoma

OCT for Pachymetry in Glaucoma

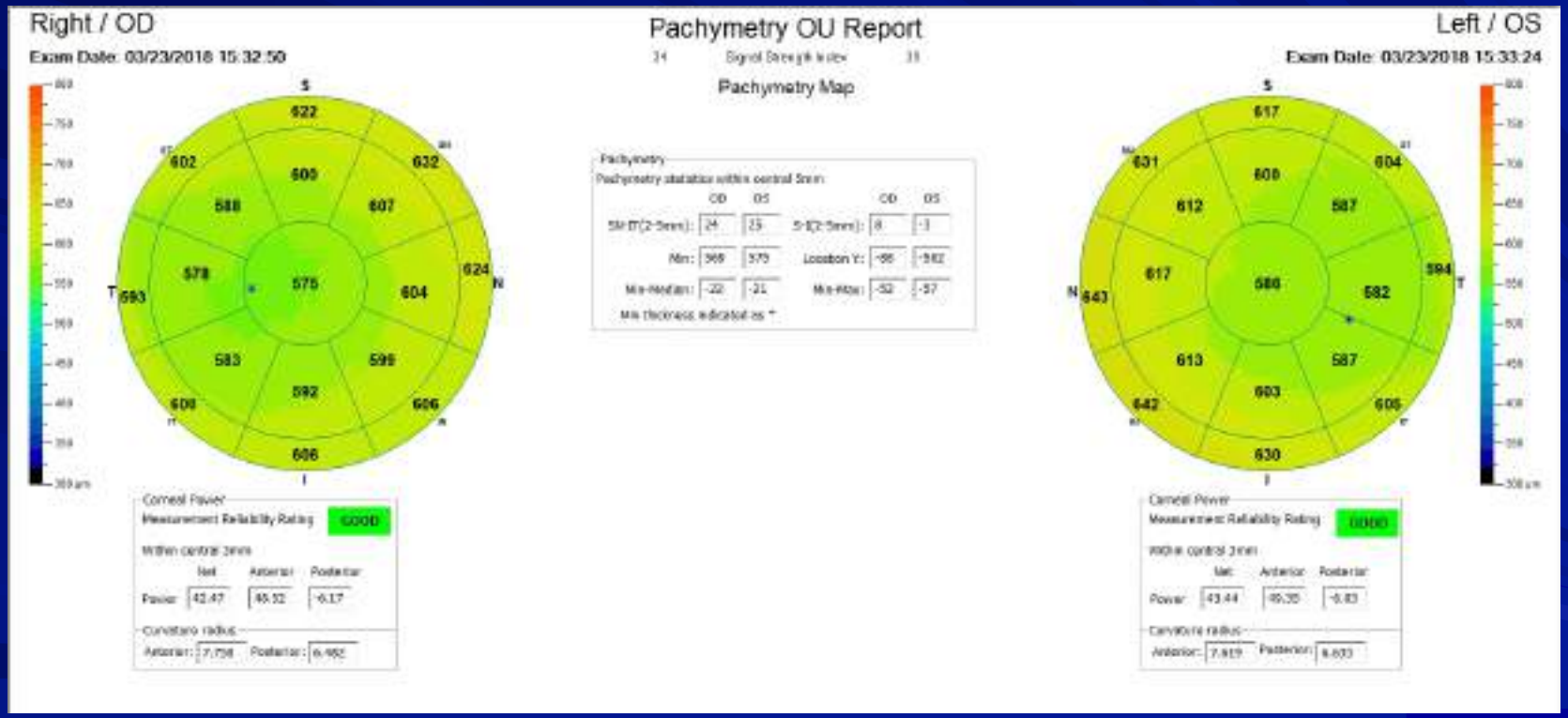

Pachymetry

Ultrasonic versus Optical versus OCT

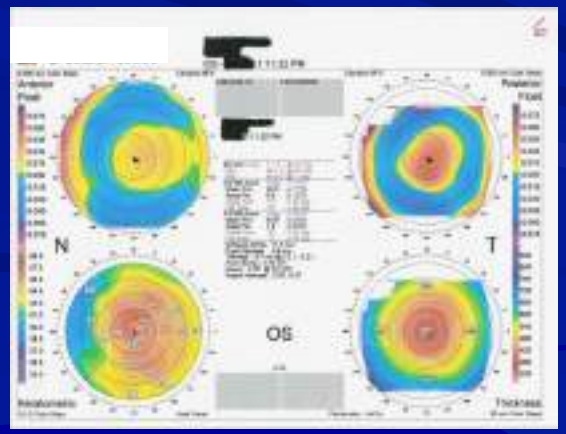

Anterior Segment Imaging
Pachymetry

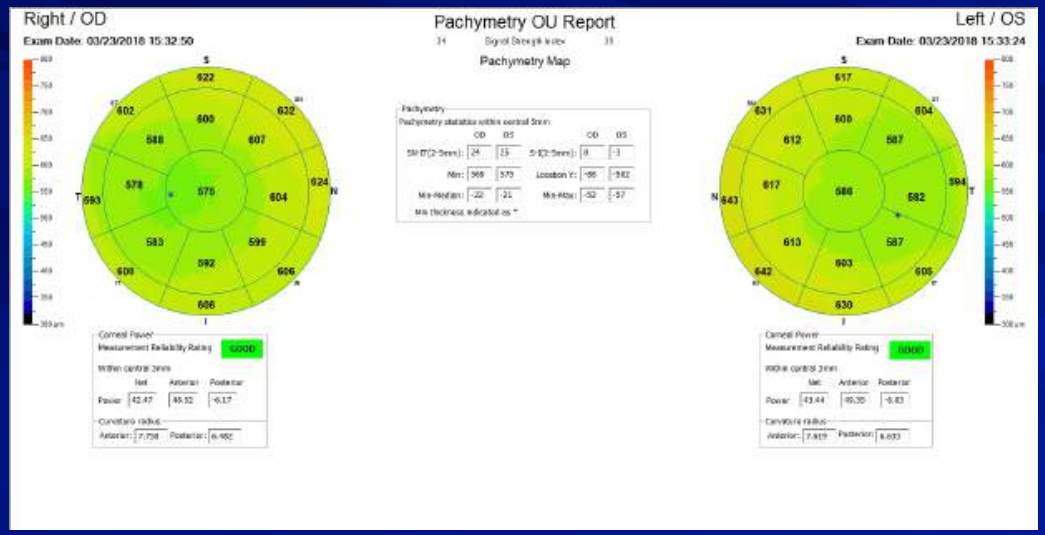

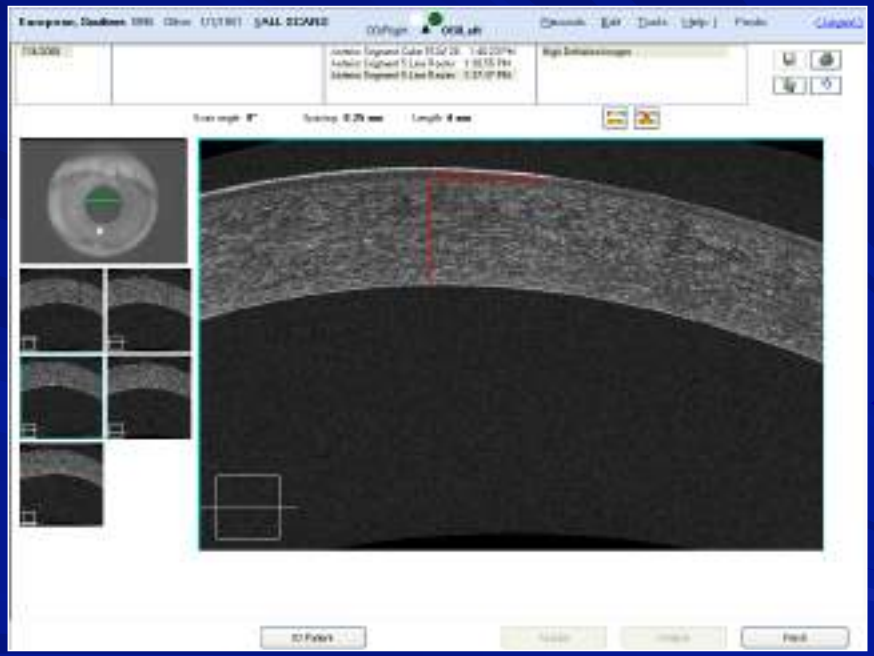

55 Year Old Men

500 microns CCT and 21 mm Hg with Goldmann

What is the true IOP?

1. 18 mm Hg
2. 21 mm Hg
3. 24 mm Hg
4. Don't Know

600 microns CCT and 21 mm Hg with Goldmann

What is the true IOP?

1. 18 mm Hg
2. 21 mm Hg
3. 24 mm Hg
4. Don't Know

Corneal Curvature

Corneal Thickness

Corneal Rigidity

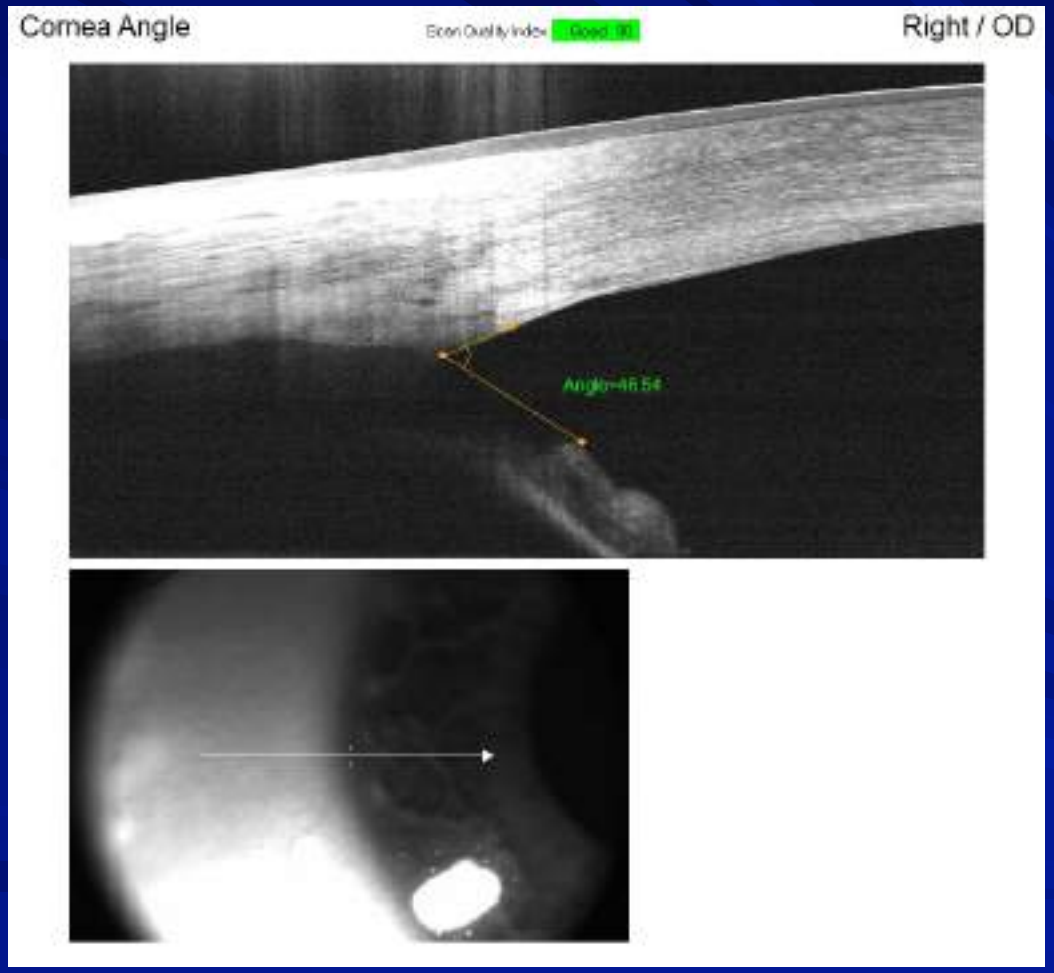
Cornea Angle
Right / OD
Angle=46.54

Less Than 15 Degrees Get Consult

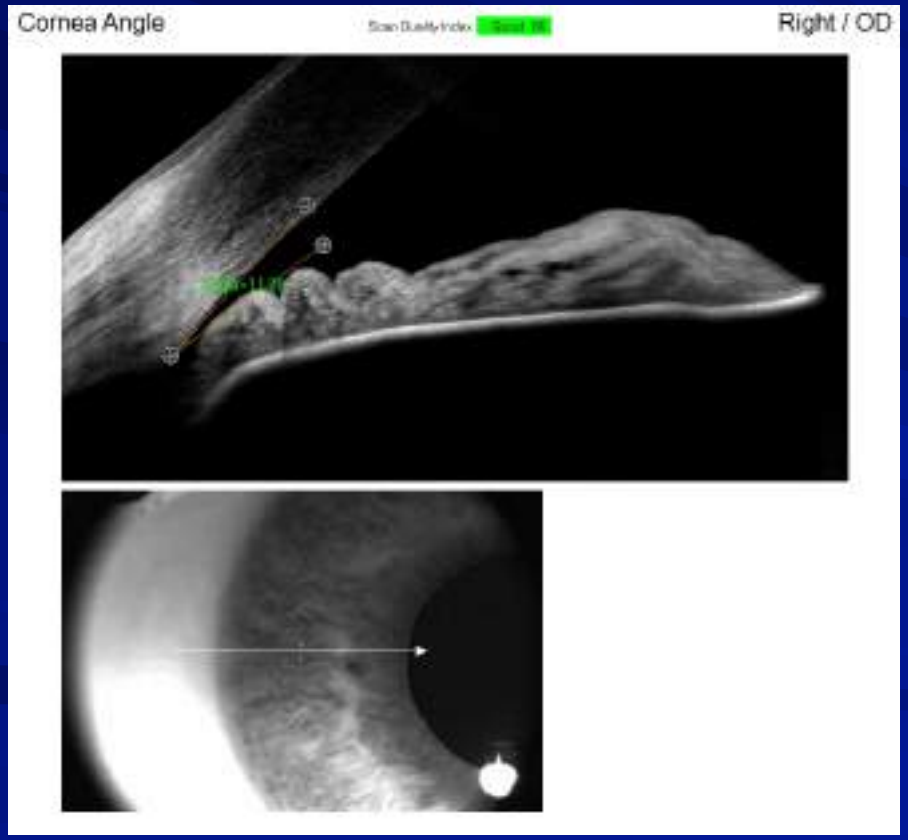

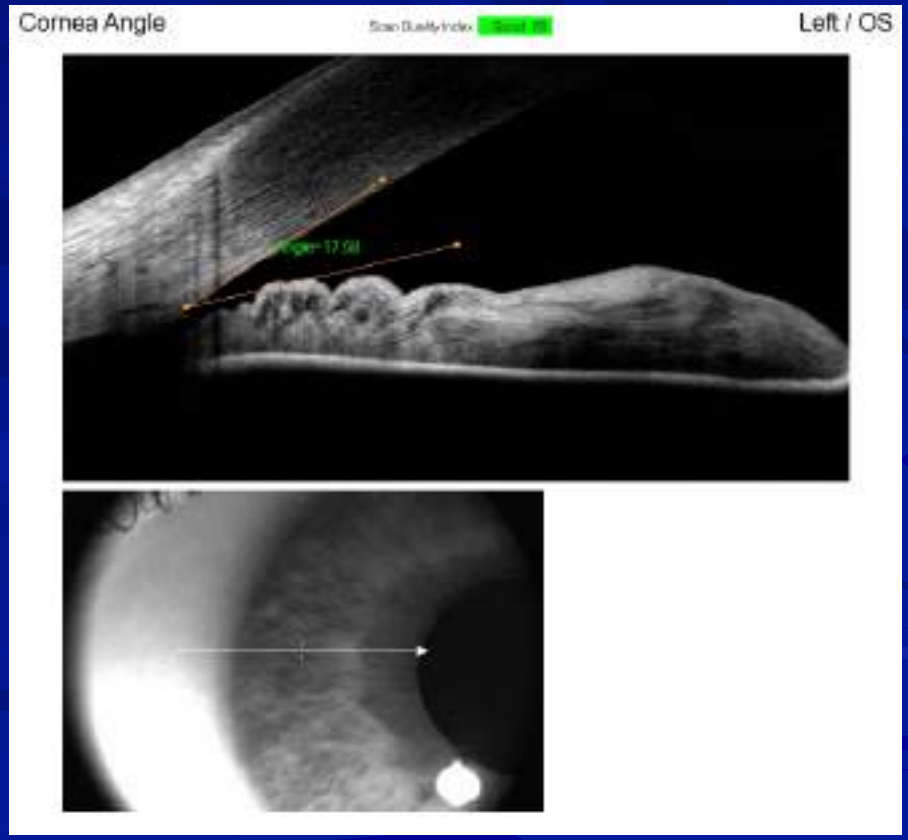

Closed Angle

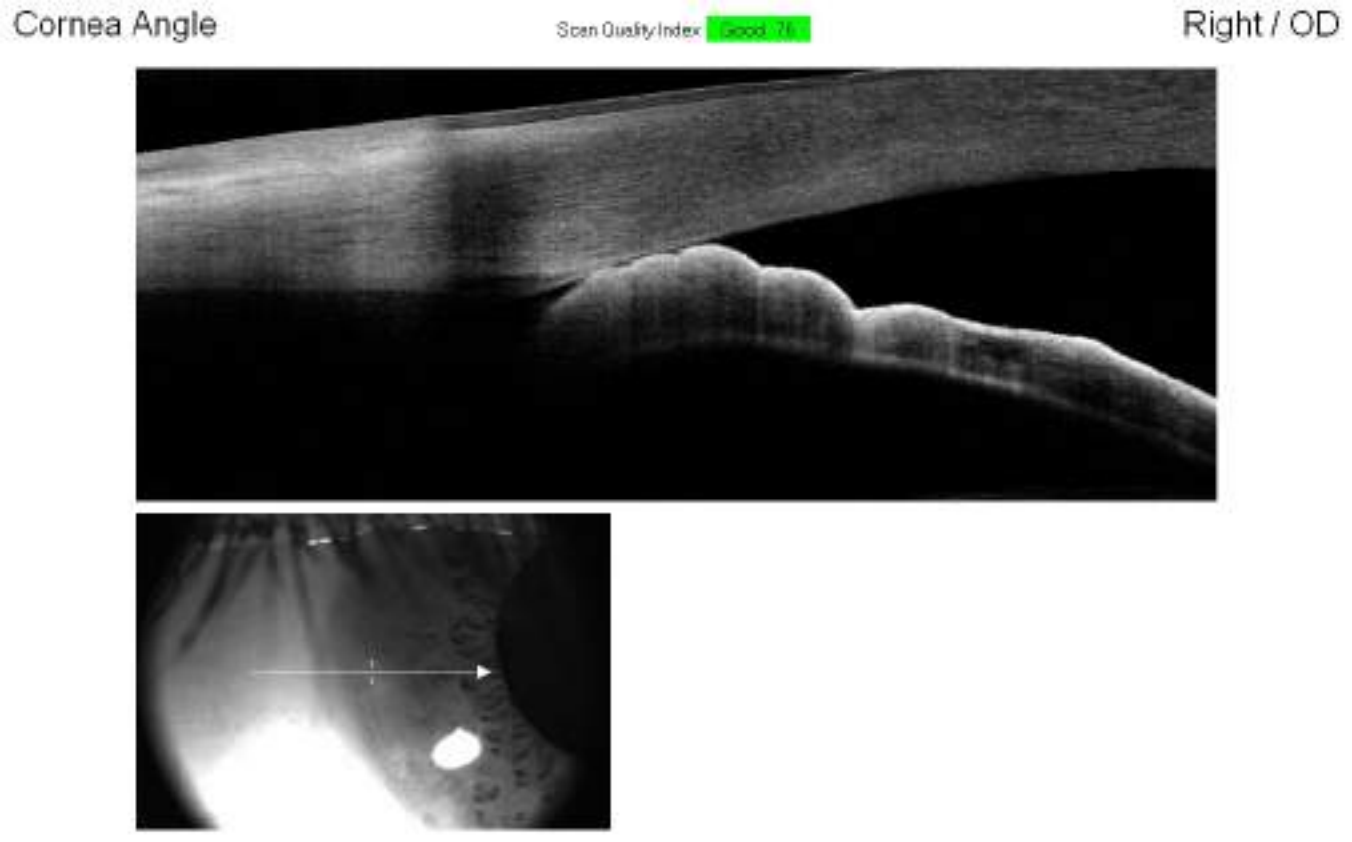

Overlay of the RNFL and GCC

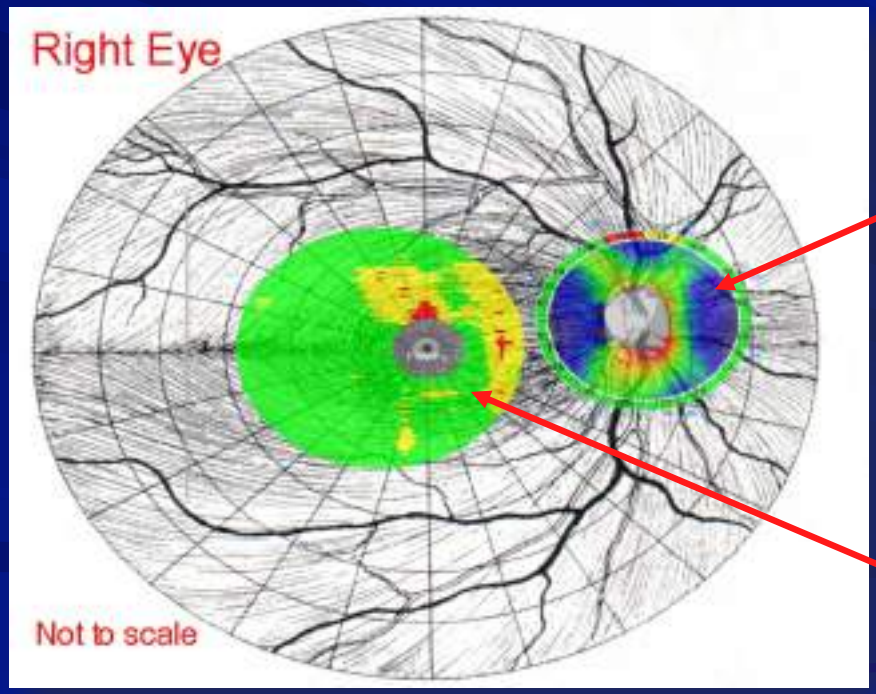

RNFL

GCC

GCC Thinning in Glaucoma

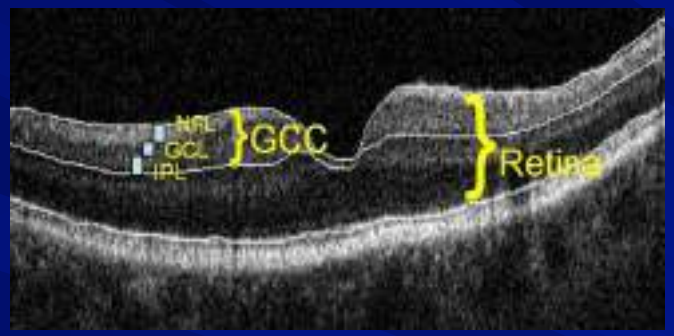

Normal

Glaucoma with thinner GCC

Green, Red, Yellow, and Blue Disease

Physiologically Normal

OCT measure structure

Green, Red, Yellow, and Blue Disease
Hints to this Disease

- If the disease is a bilateral disease
  - Glaucoma
    - It is usually asymmetric
- If the scans are symmetric
  - Then it most likely not disease – physiologically normal
  - Anatomical variation
    - Normal for that patient
- Another hint is the GCC expected values
  - 85-100 microns
  - 92-95 microns

Symmetry and What is Being Tested

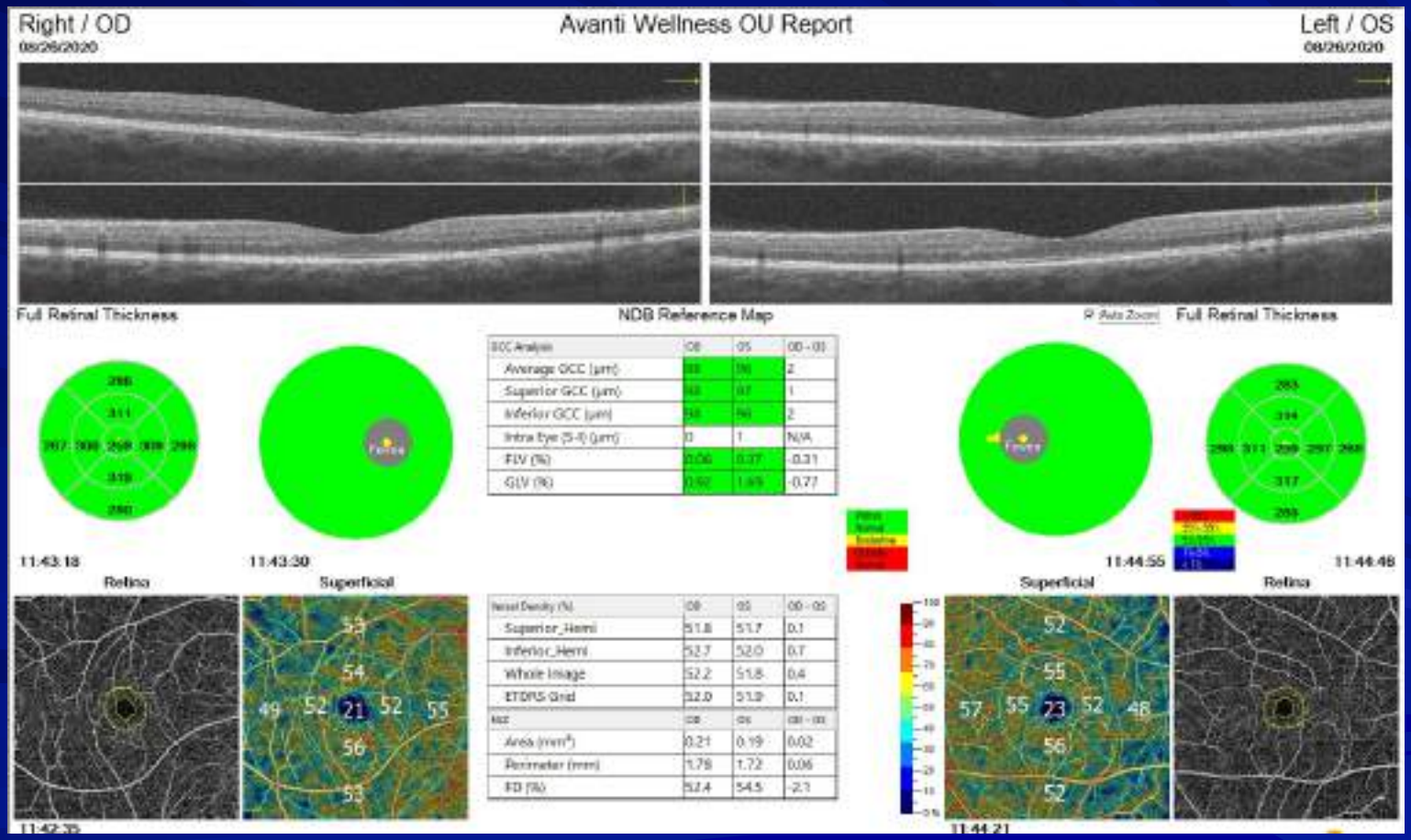

46-year-old woman with red-yellow disease

- OD -0.75 20/20
- OS -1.25 20/20

- Systemic hx: thyroid dysfunction, high cholesterol
  - Medications for the above

- IOPs 15 mm Hg OU 8:30 am

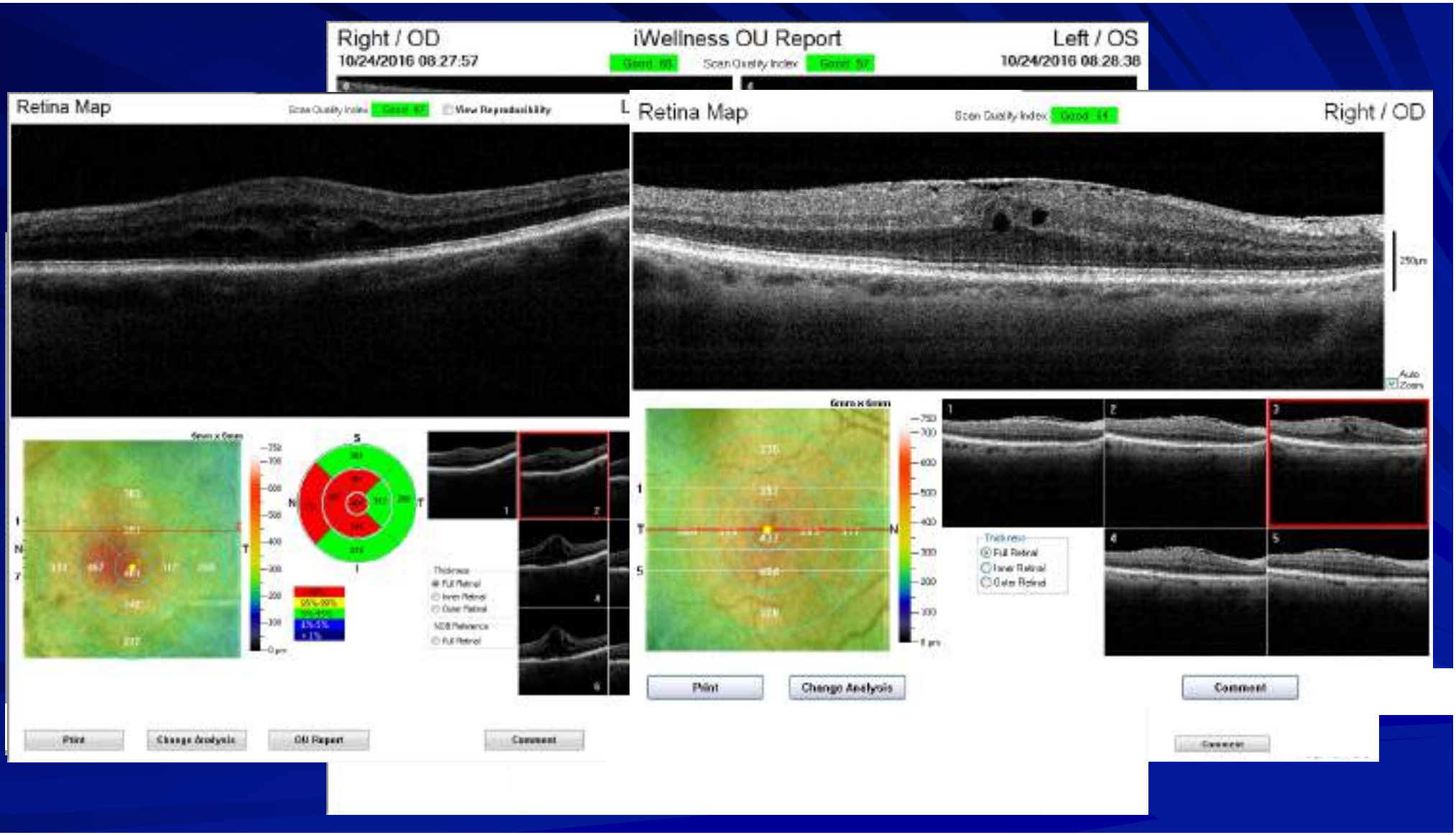
Right / OD
10/24/2016 08:27:57
iWellness OU Report
Scan Quality Index
Left / OS
10/24/2016 08:28:38
Retina Map
View Reproducibility
Retina Map
Scan Quality Index
Right / OD
Print
Change Analysis
OU Report
Comment
Print
Change Analysis
Comment

63-year-old woman with red, yellow, blue, and green disease

- OD plano/ +2.00 20/20
- OS -0.50/ +2.00 20/20

- IOPs 15-18 mm Hg OU 2011-2015

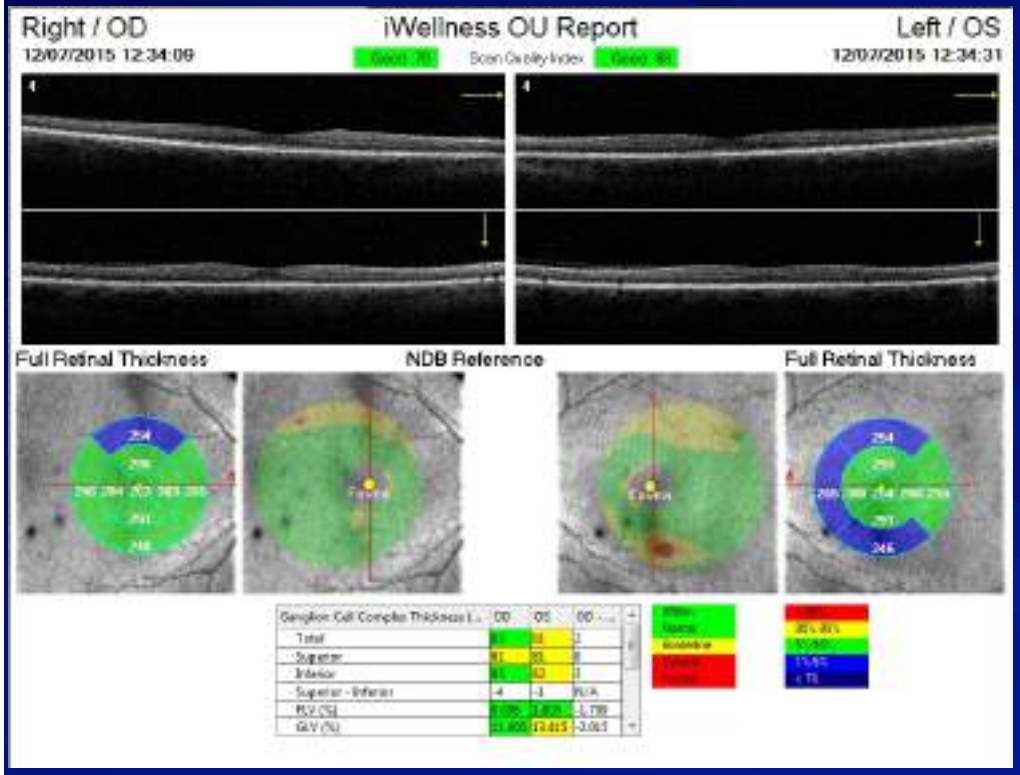
Right / OD
iWellness OU Report
Left / OS
12/07/2015 12:34:09
12/07/2015 12:34:31
Full Retinal Thickness
NDB Reference
Full Retinal Thickness

2015

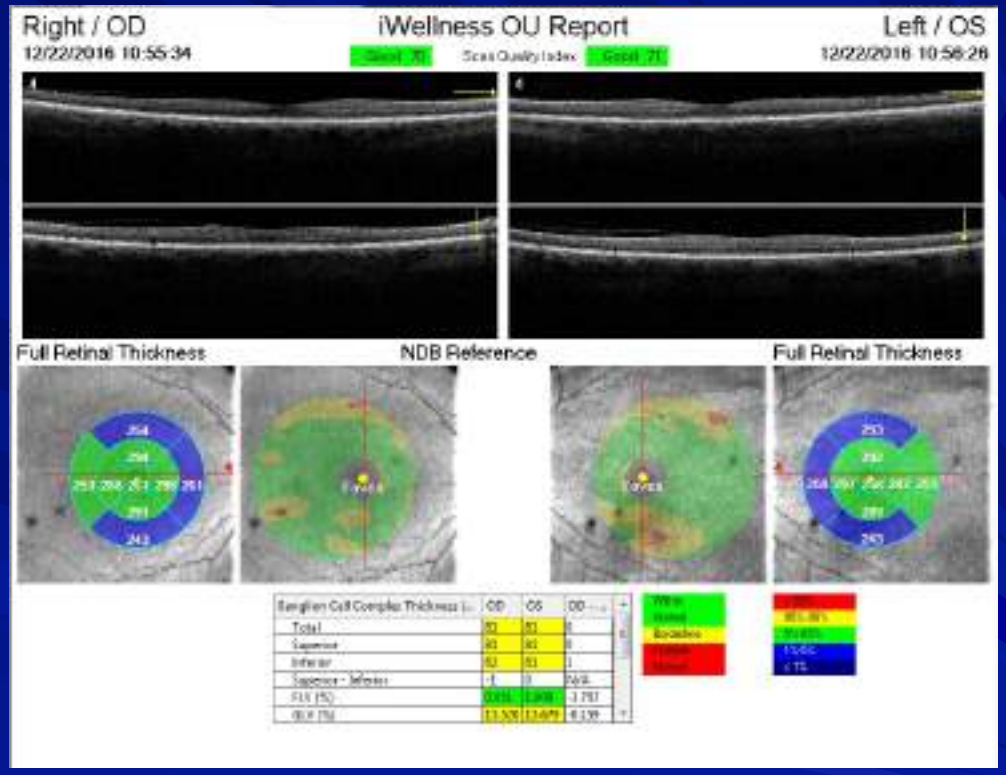
Right / OD
iWellness OU Report
Left / OS
12/22/2016 10:55:34
12/22/2016 10:56:26
Full Retinal Thickness
NDB Reference
Full Retinal Thickness

2016

58-year-old with yellow disease

- OD +1.00 20/20
- OS +1.25 20/20

- IOPs: 13/15 mm Hg at 11:24 am

- (pay attention to FLV and GLV)

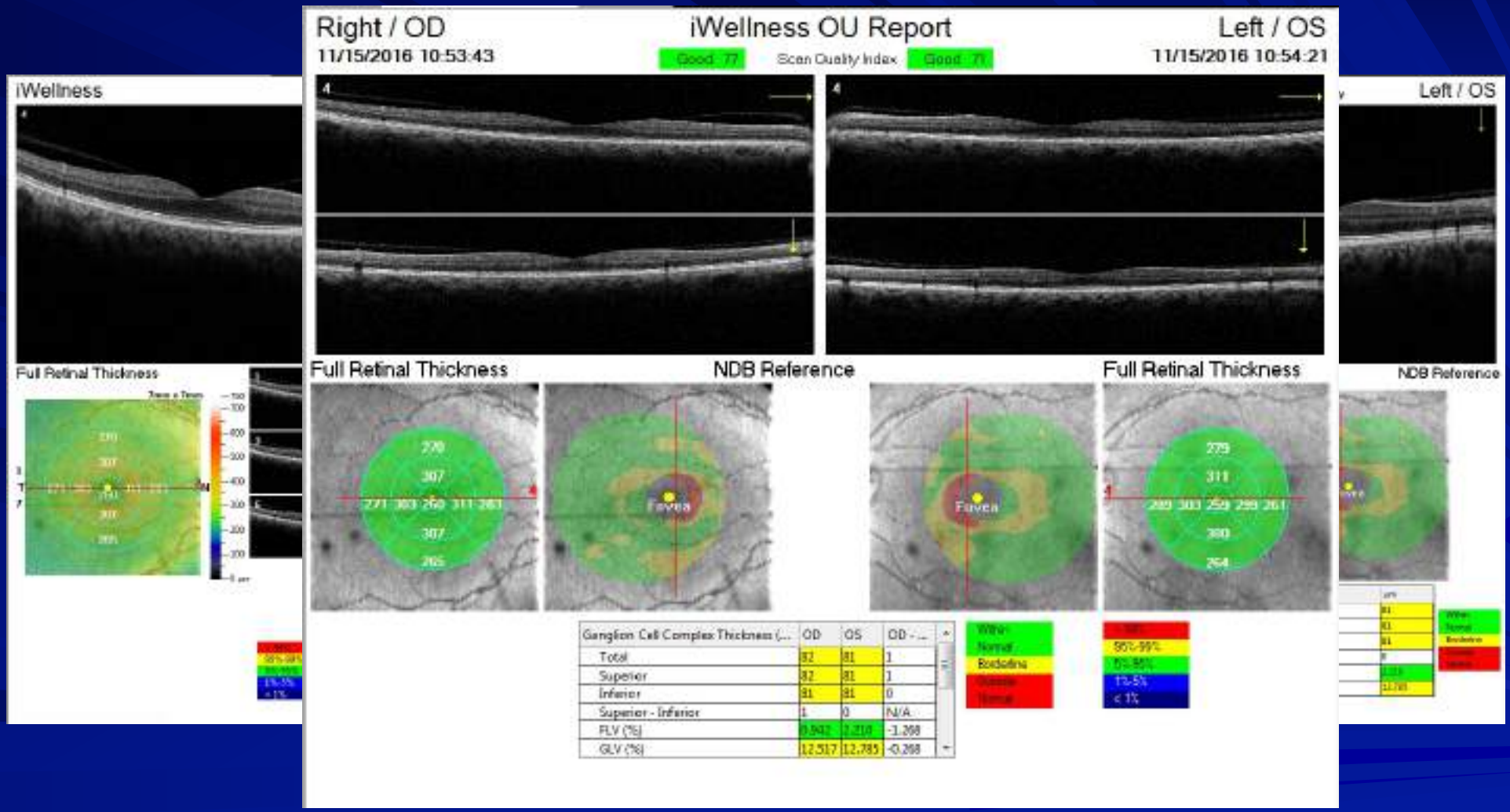
iWellness
Full Retinal Thickness
Right / OD
11/15/2016 10:53:43
iWellness OU Report
Good 77
Scan Quality Index
Good 71
Left / OS
11/15/2016 10:54:21
Full Retinal Thickness
NDB Reference
Fovea
Full Retinal Thickness
NDB Reference
Fovea
Left / OS
Ganglion Cell Complex Thickness (...
OD
OS
OD - ...
Total
Superior
Inferior
Superior - Inferior
FLV (%)
GLV (%)
Normal
Borderline
< 1%

40 yo man with red, blue, green disease

- OD -7.50 – 0.75 x 110 20/20
- OS -7.50 – 0.75 x 105 20/20

- IOPs: 15/13 mm Hg at 6:30 pm

March 16, 2015

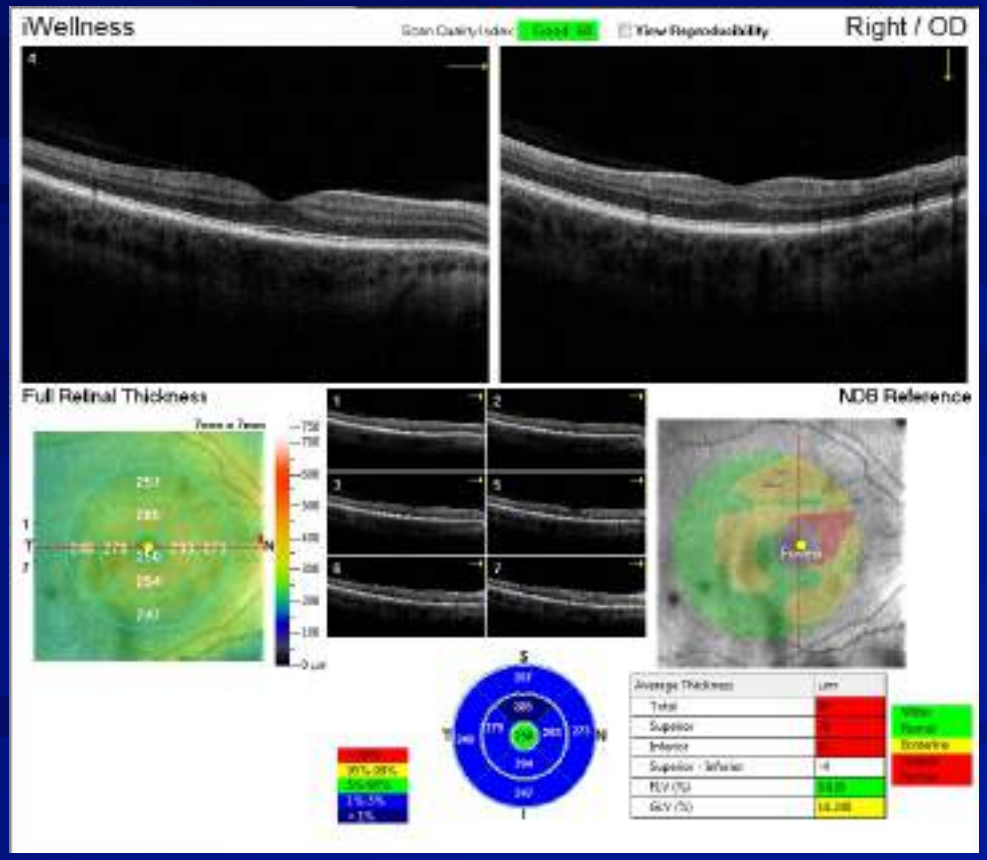

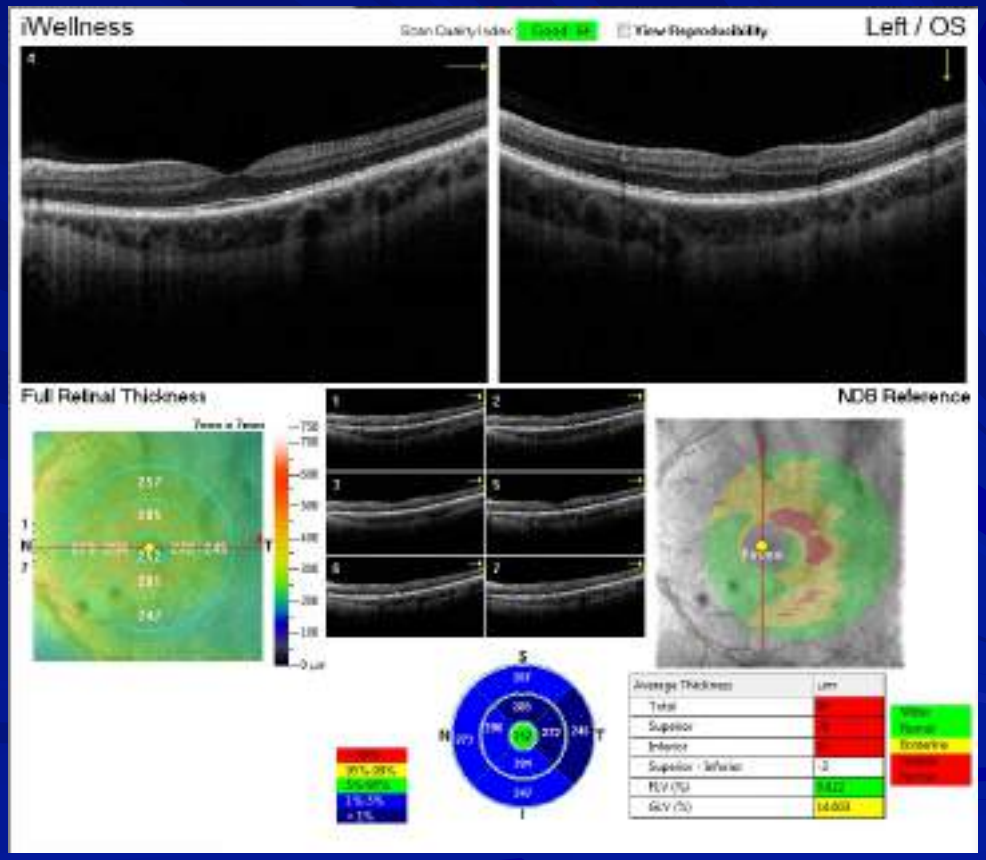

January 9, 2017

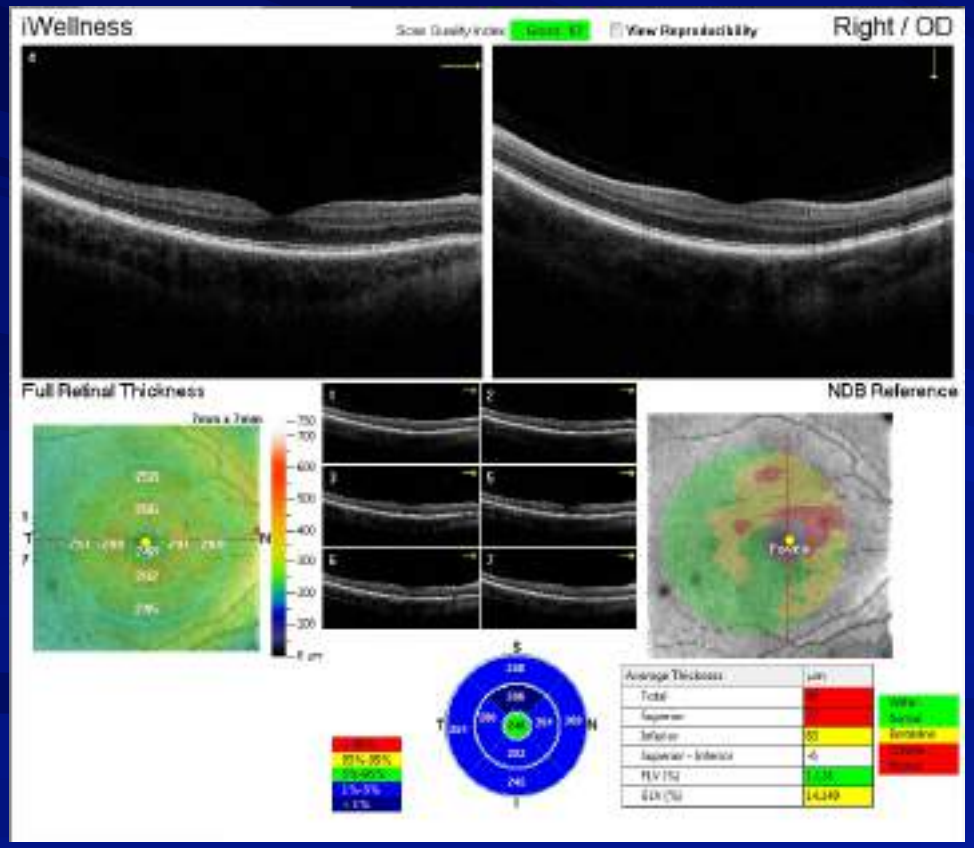

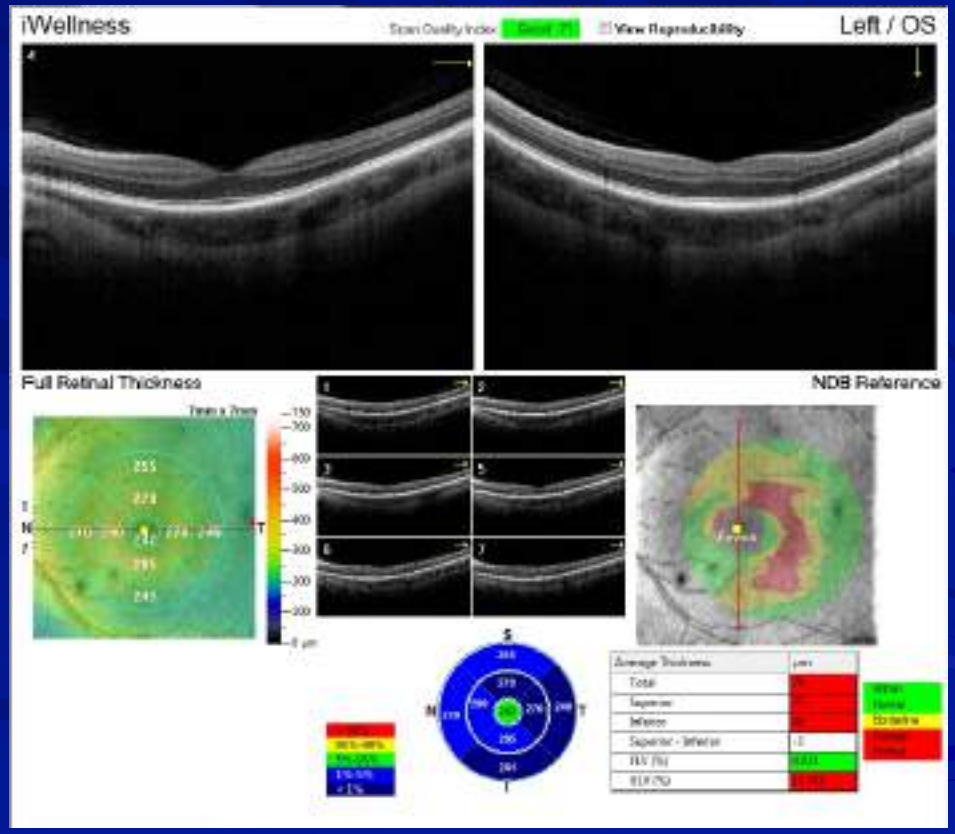

22 months apart

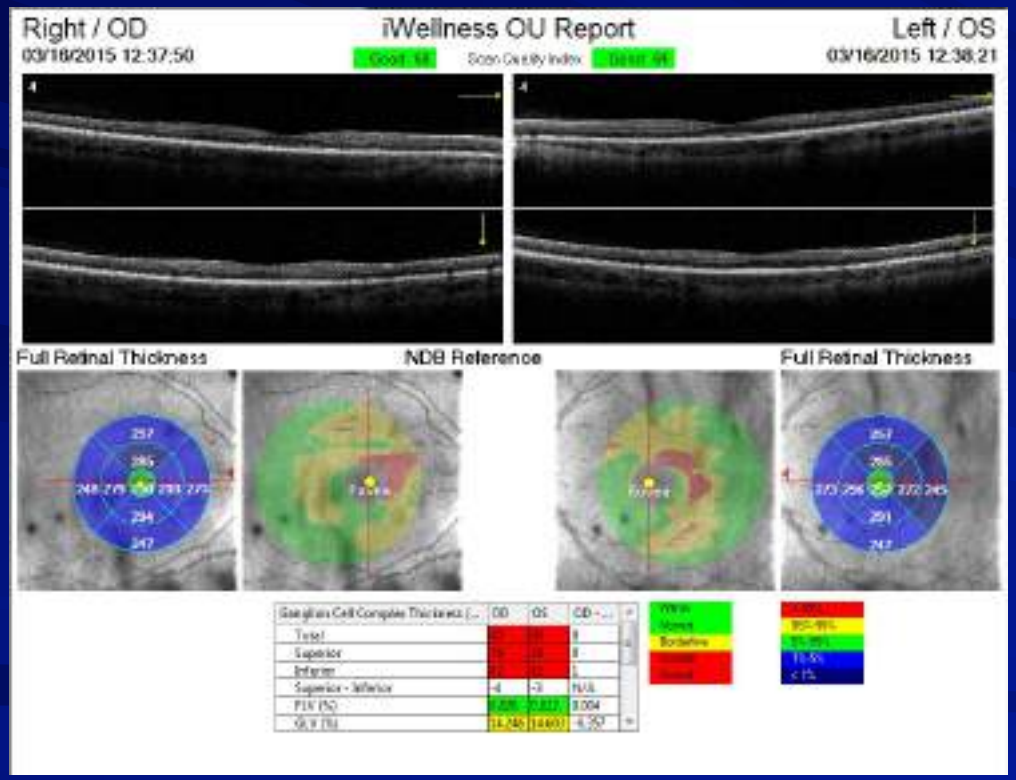

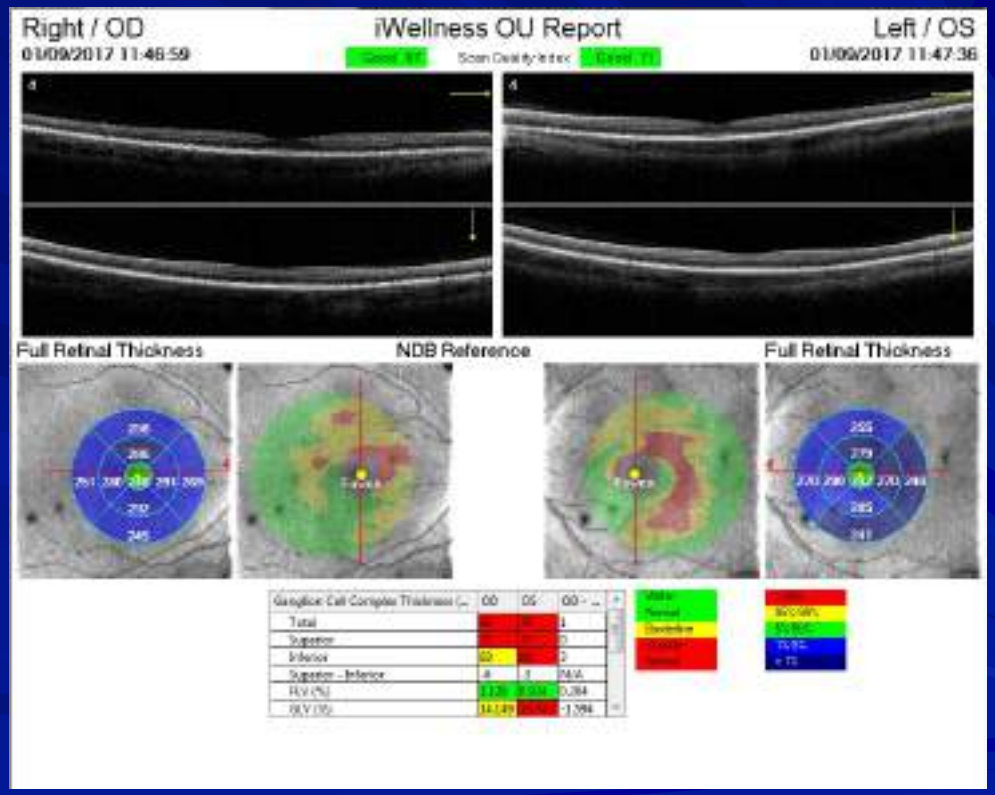

79 year-old-woman with DM

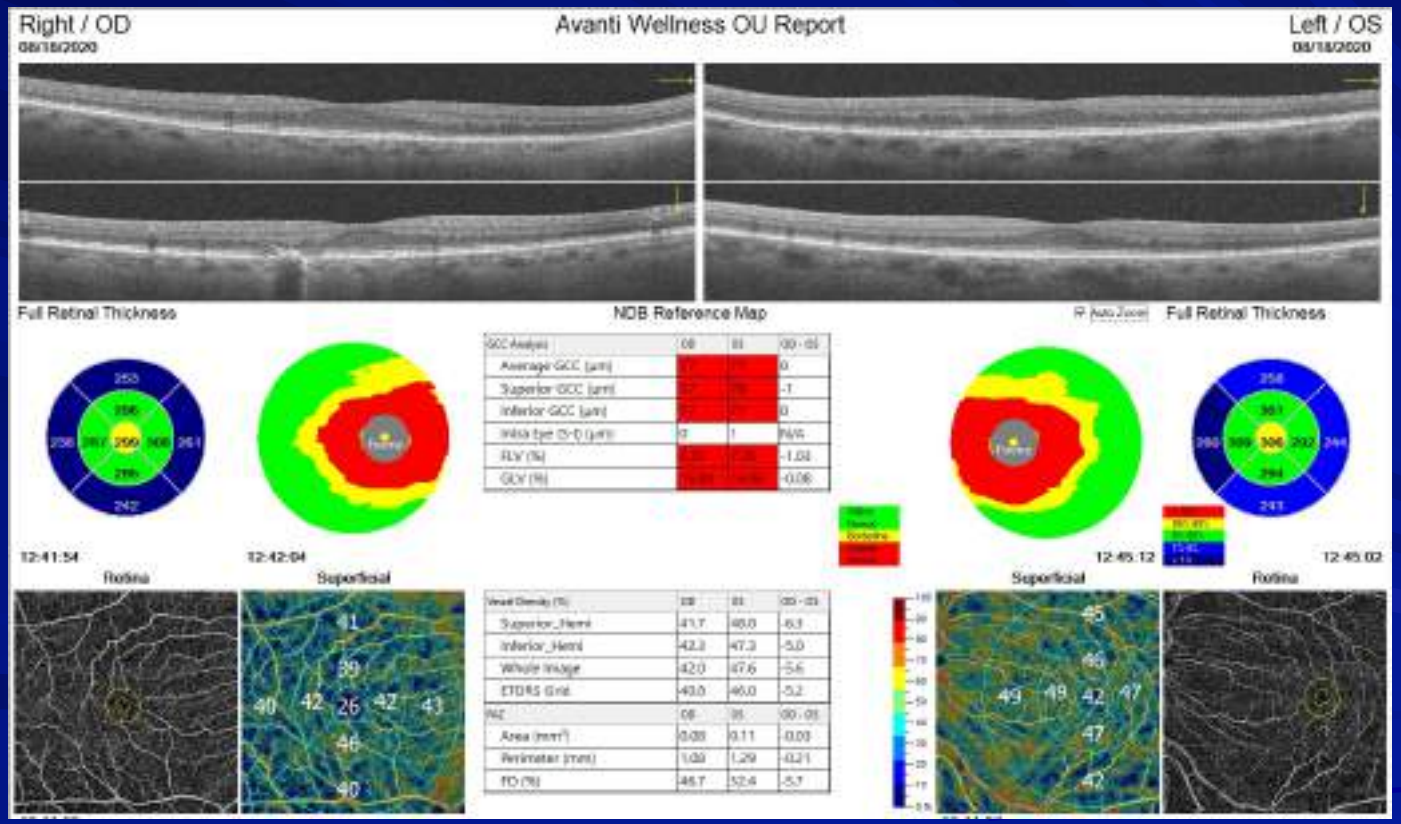

Glaucoma

NFL and GCC

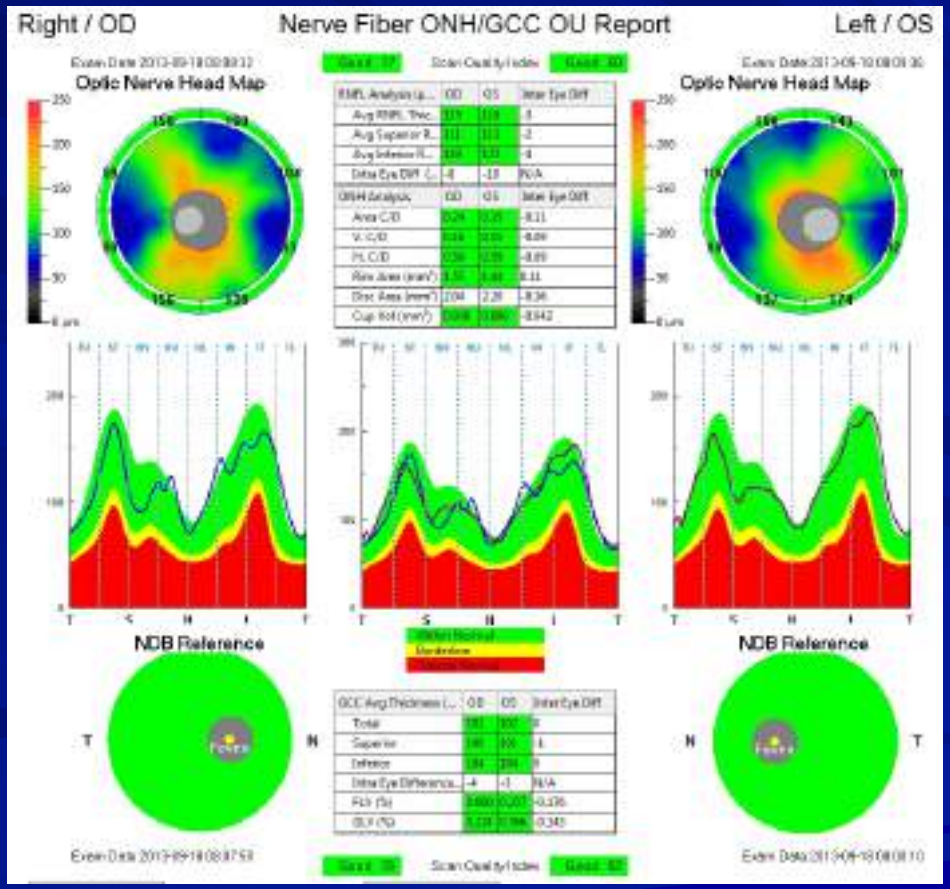
Right / OD
Nerve Fiber ONH/GCC OU Report
Left / OS
Optic Nerve Head Map
Optic Nerve Head Map
NDB Reference
NDB Reference

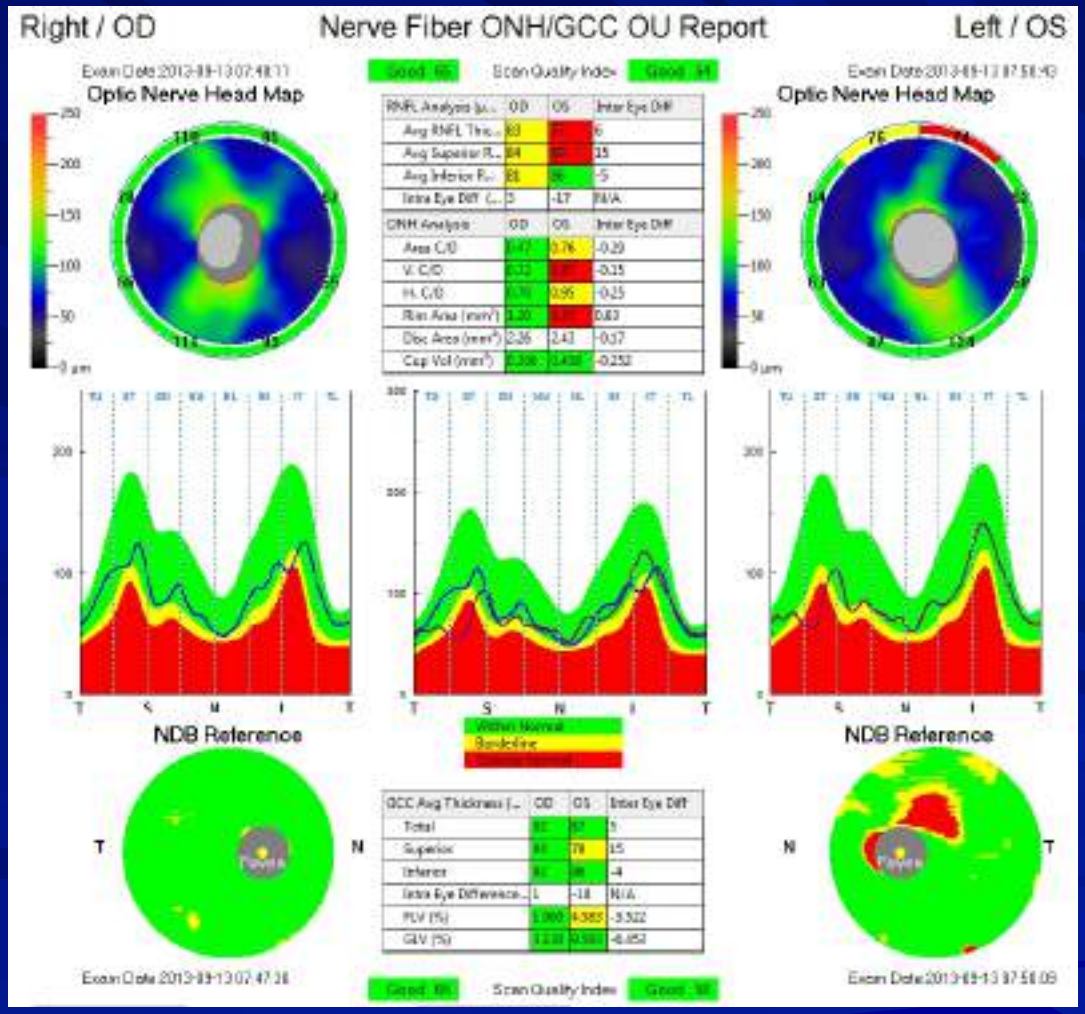
Right / OD
Nerve Fiber ONH/GCC OU Report
Left / OS
Optic Nerve Head Map
Optic Nerve Head Map
NDB Reference
NDB Reference
T
N
N
T

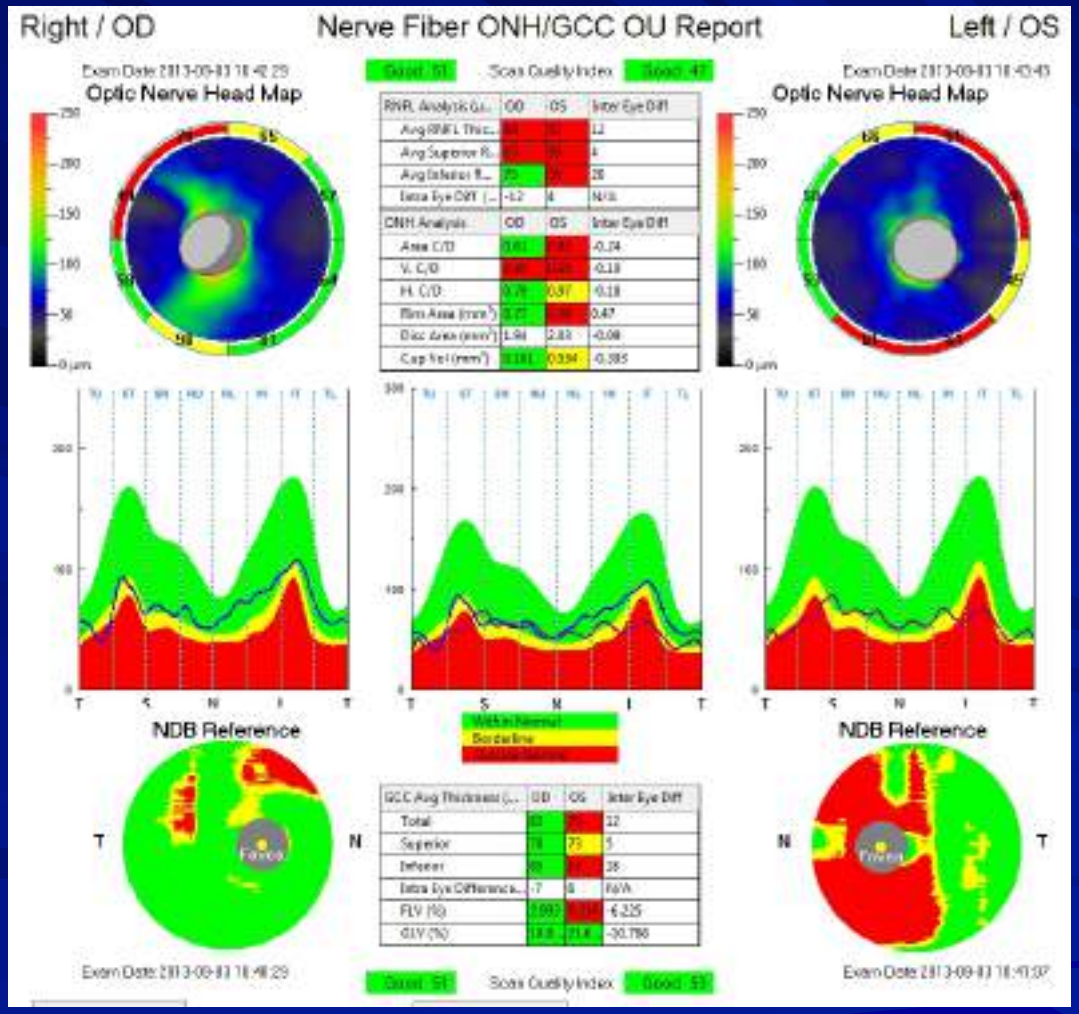
Right / OD
Nerve Fiber ONH/GCC OU Report
Left / OS
Optic Nerve Head Map
Optic Nerve Head Map
NDB Reference
NDB Reference
T
N
N
T

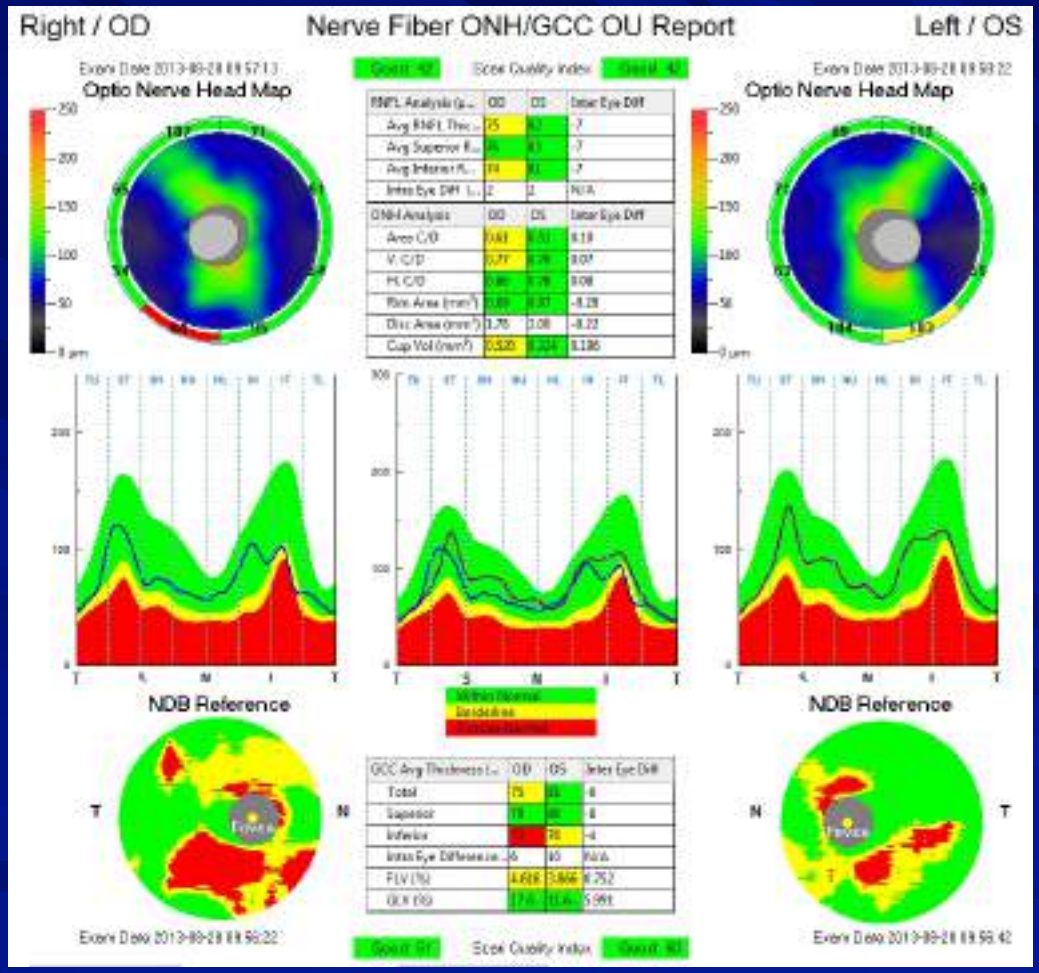
Right / OD
Nerve Fiber ONH/GCC OU Report
Left / OS
Optic Nerve Head Map
Optic Nerve Head Map
NDB Reference
NDB Reference

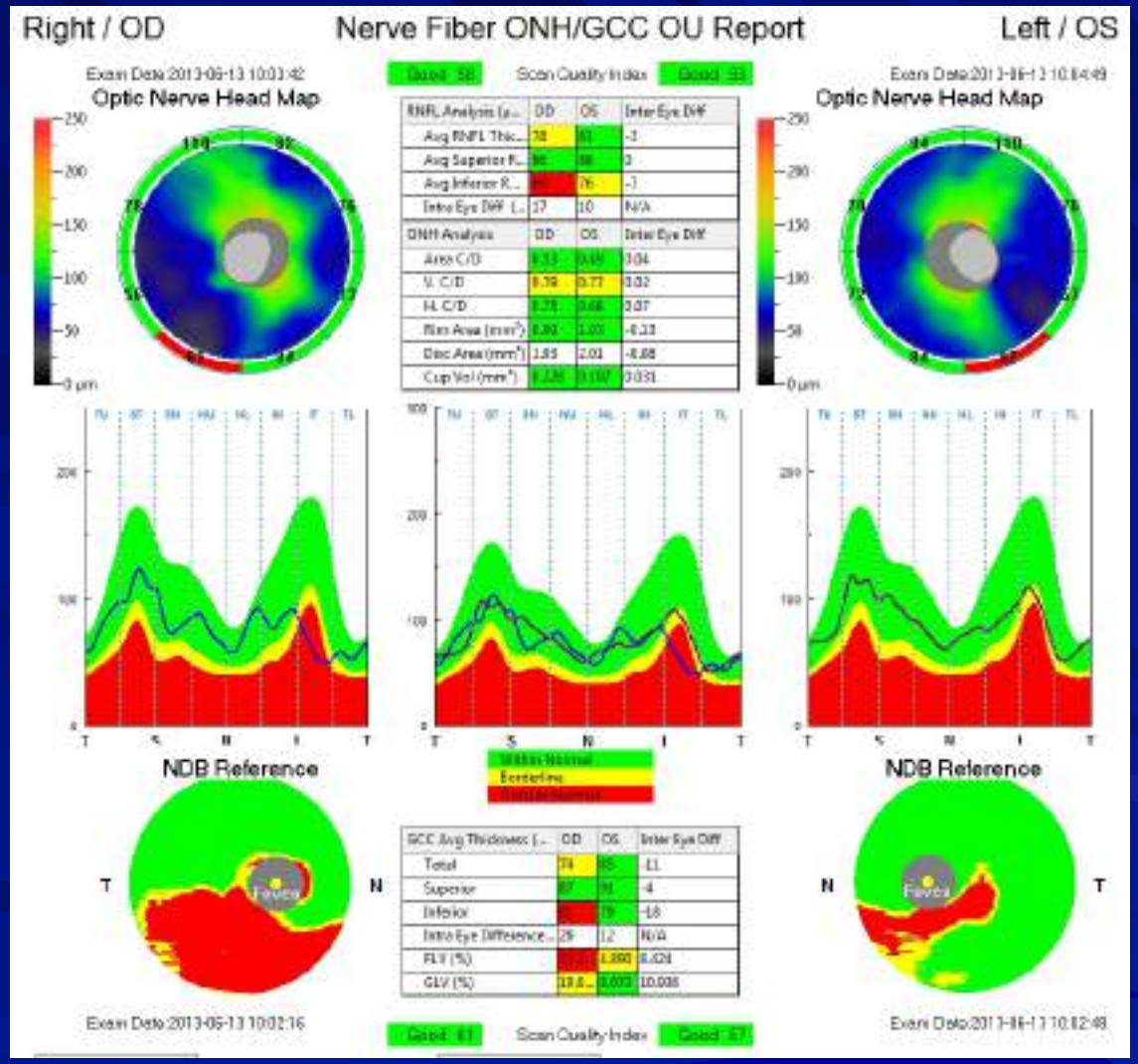
Right / OD
Nerve Fiber ONH/GCC OU Report
Left / OS
Optic Nerve Head Map
Optic Nerve Head Map
NDB Reference
NDB Reference
Fovea
Fovea
T
N
N
T

POAG

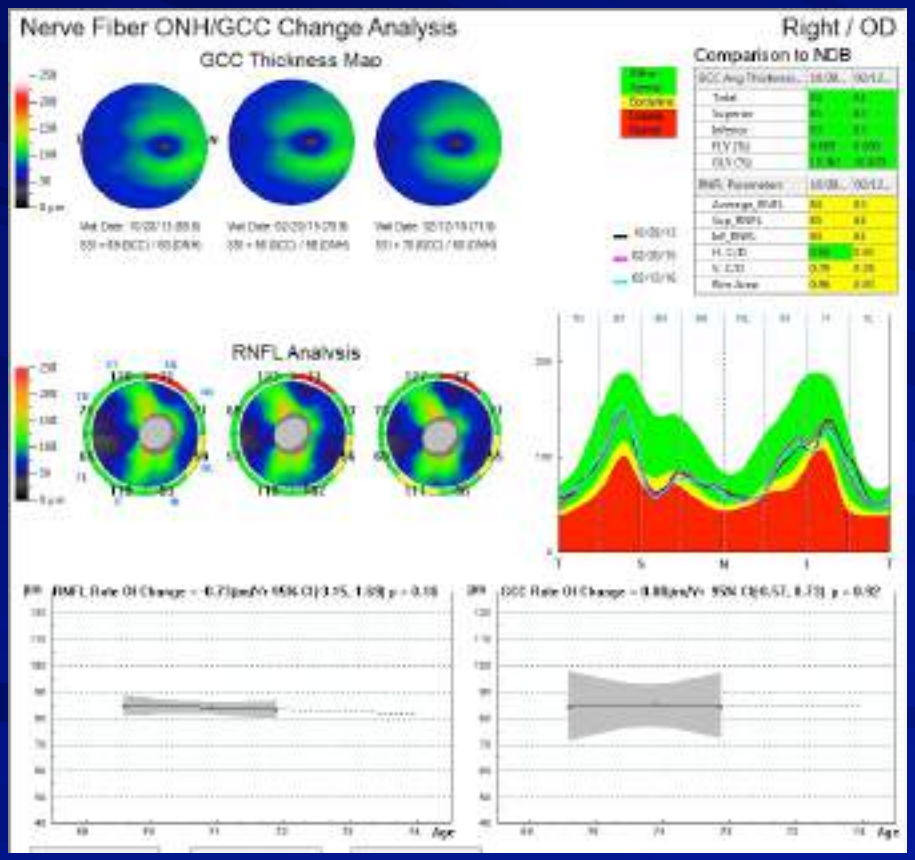
Nerve Fiber ONH/GCC Change Analysis
Right / OD
GCC Thickness Map
Comparison to NDB
RNFL Analysis

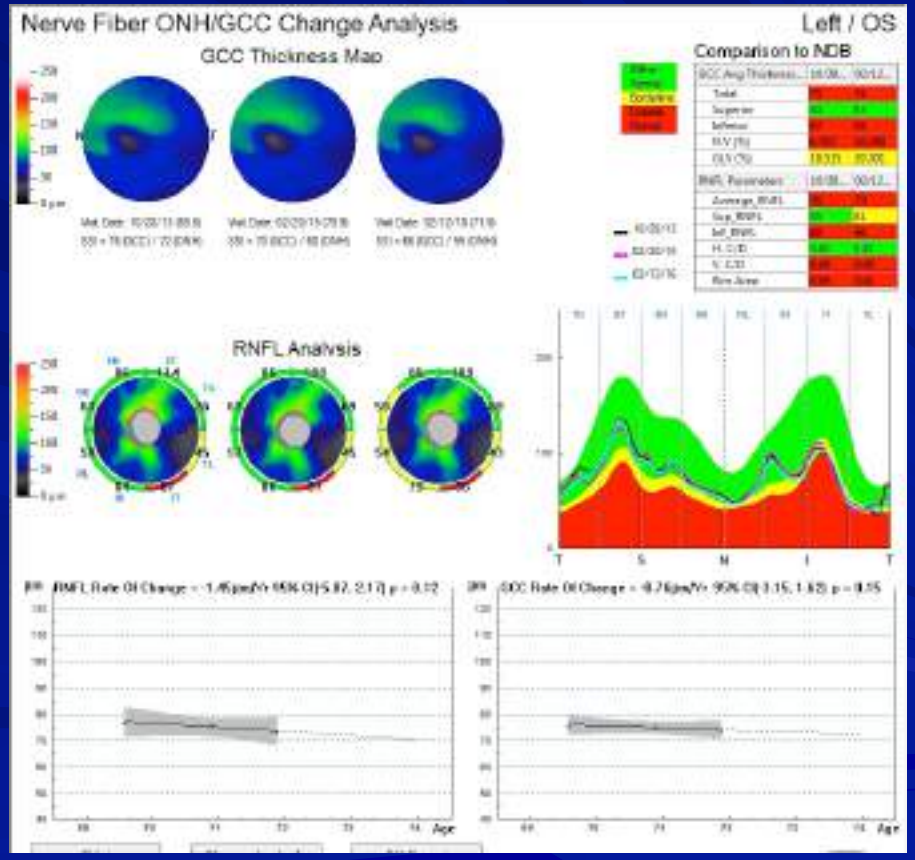
Nerve Fiber ONH/GCC Change Analysis
Left / OS
GCC Thickness Map
Comparison to NDB
RNFL Analysis

POAG

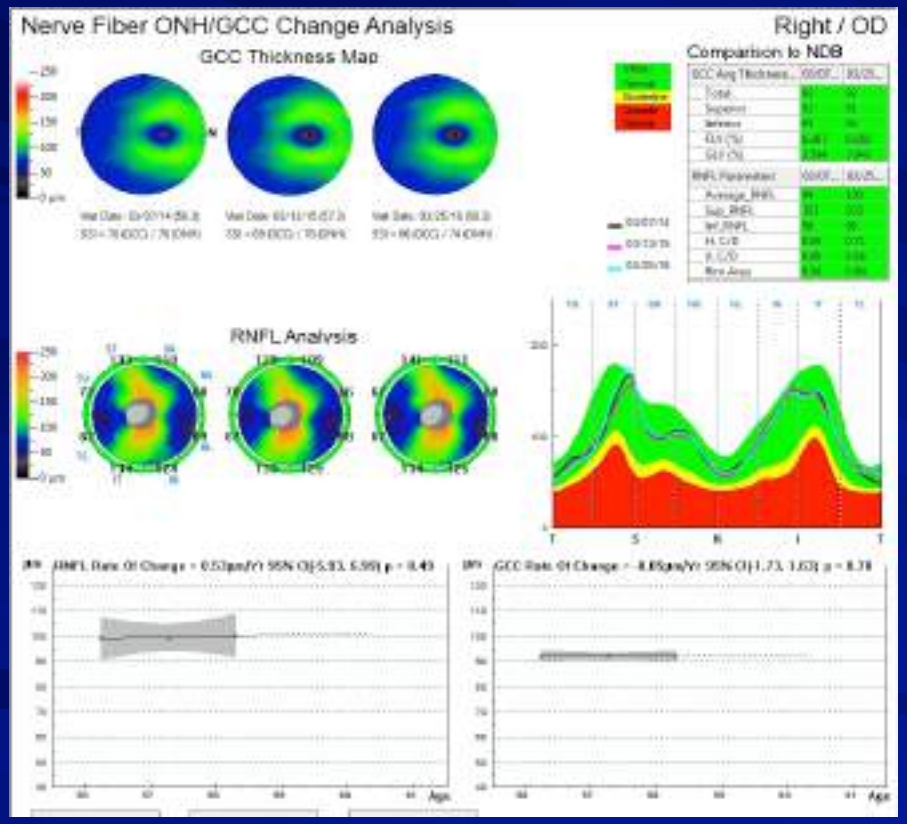
Nerve Fiber ONH/GCC Change Analysis
Right / OD
GCC Thickness Map
Comparison to NDB
RNFL Analysis

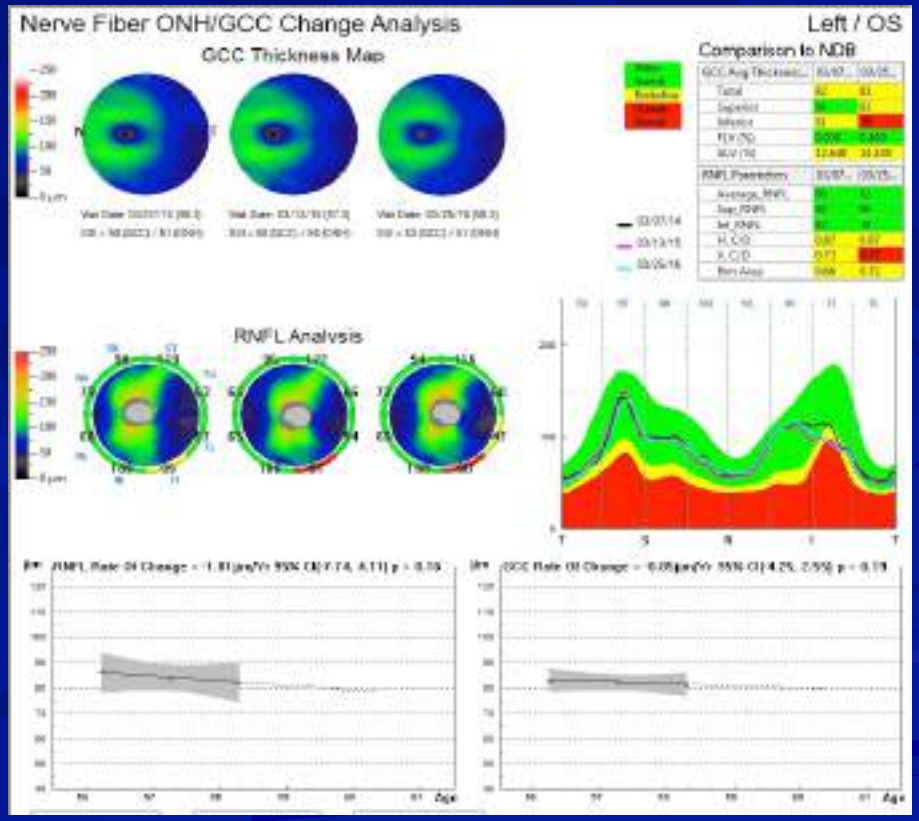
Nerve Fiber ONH/GCC Change Analysis
Left / OS
GCC Thickness Map
Comparison to NDB
RNFL Analysis

POAG

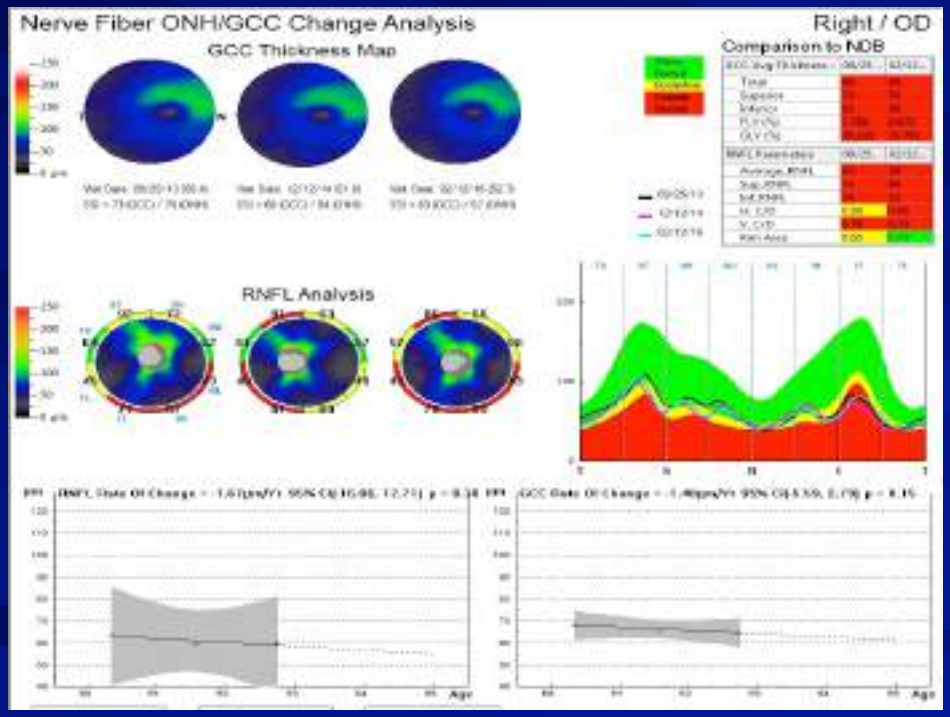
Nerve Fiber ONH/GCC Change Analysis
Right / OD
GCC Thickness Map
Comparison to NDB
RNFL Analysis

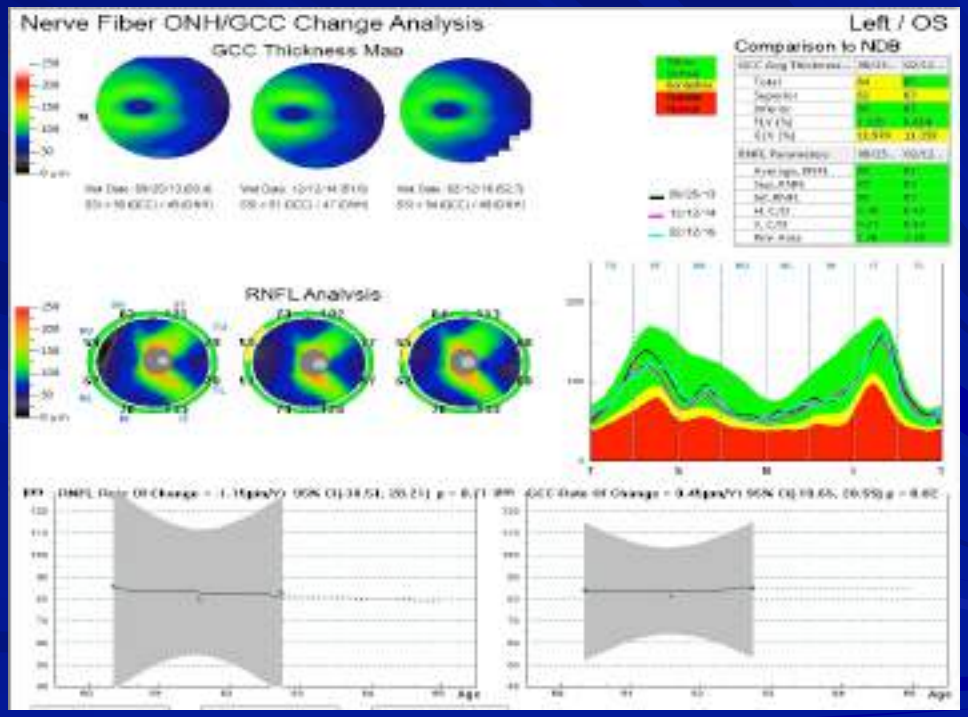
Nerve Fiber ONH/GCC Change Analysis
Left / OS
GCC Thickness Map
Comparison to NDB
RNFL Analysis

Glaucoma Suspect strong family history

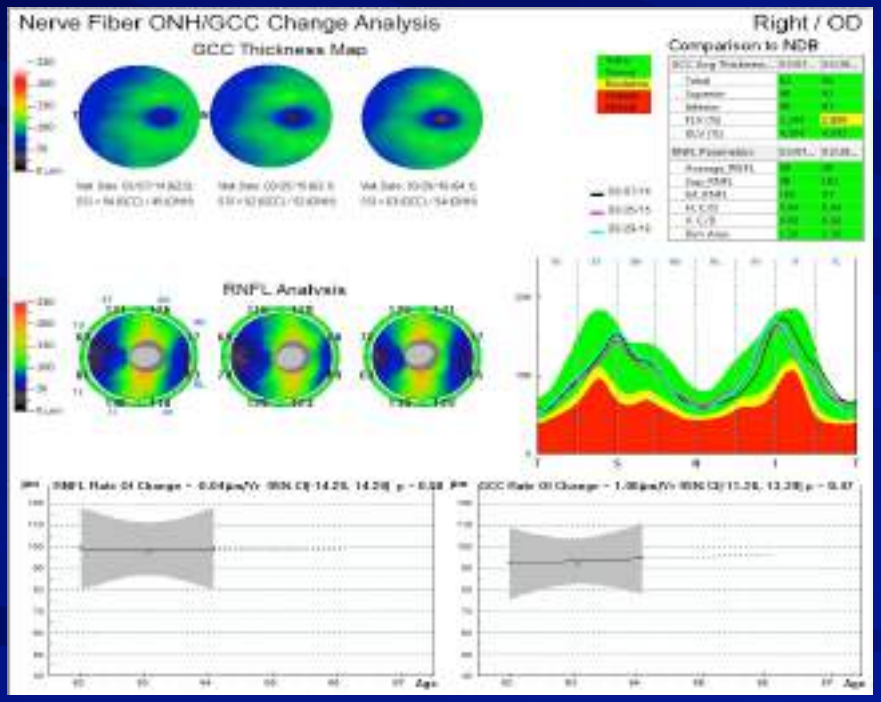

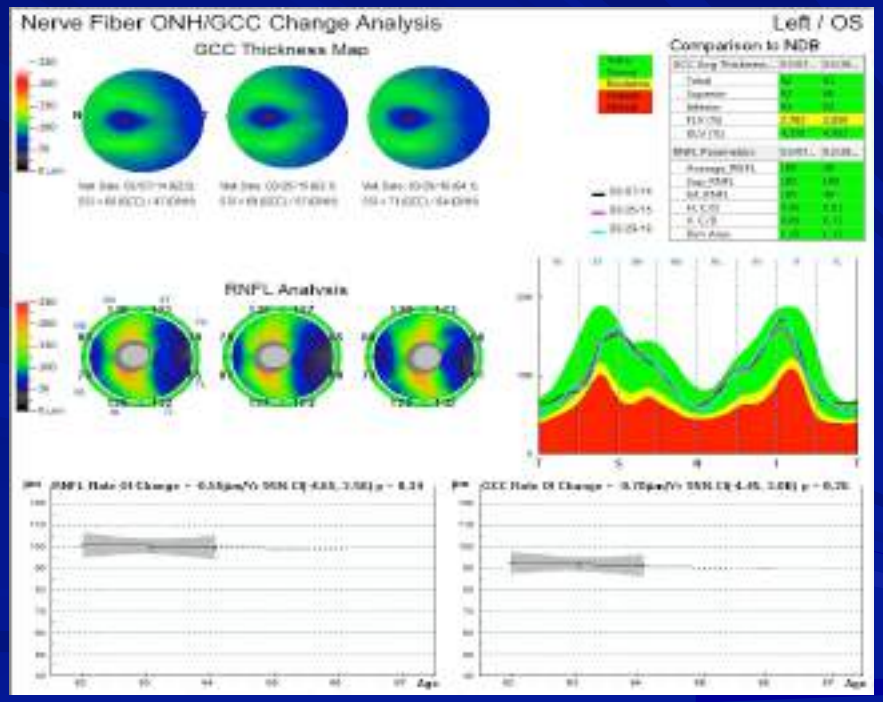

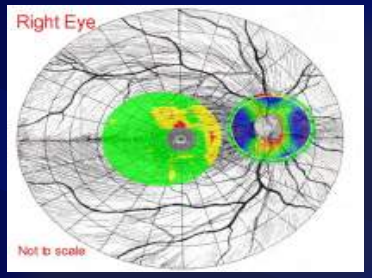

Next Generation Glaucoma Analysis with OCT + OCTA

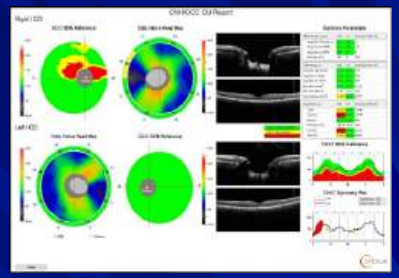

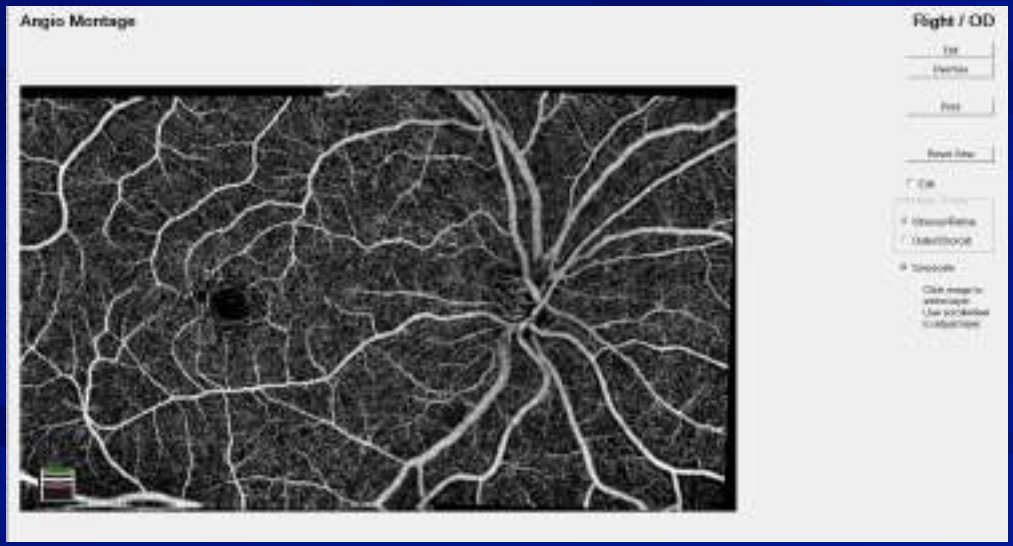

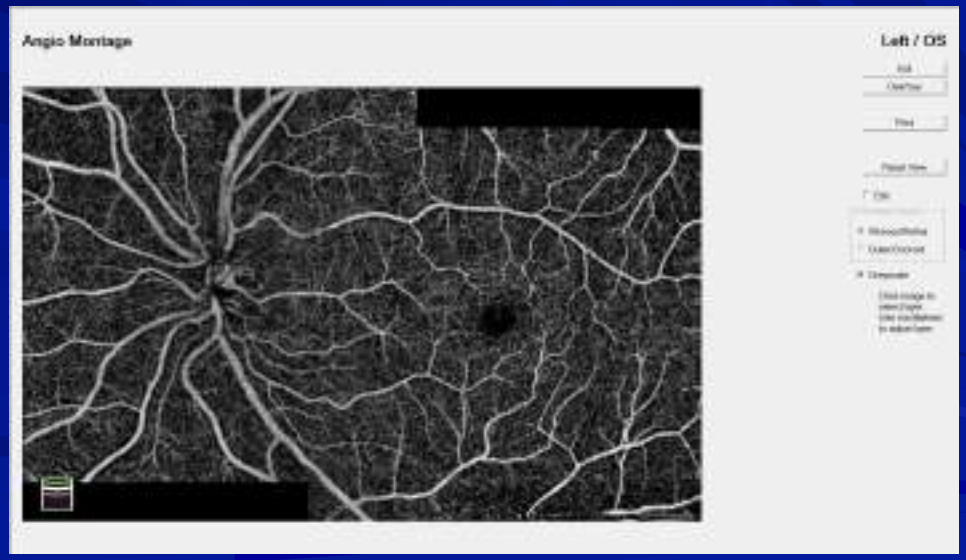

Learn What Normal Looks Like

Disc:
Radial Peripapillary
Capillaries

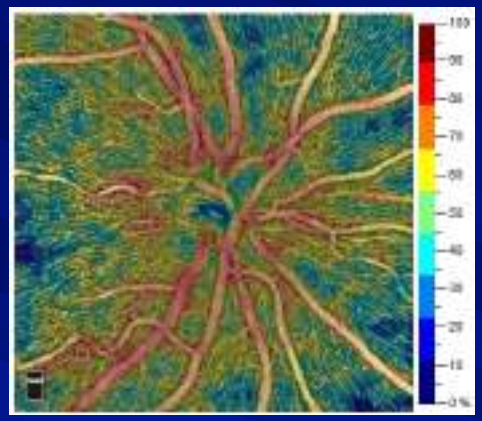

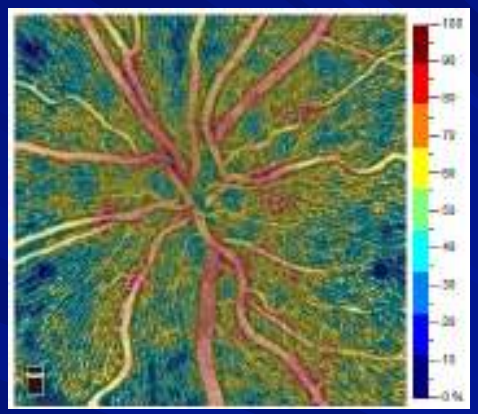

Retina:
Superficial Vascular
Complex



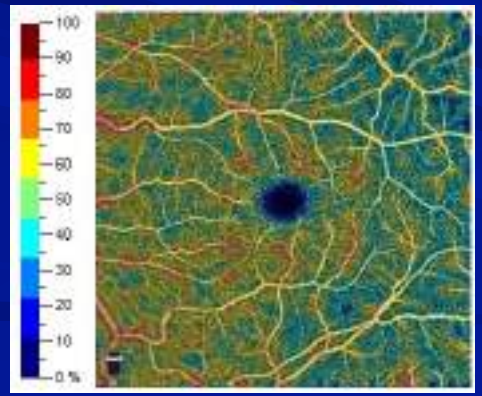

OD

OS

What Does Glaucoma Look Like?

Normal | Moderate Glaucoma | Advanced Glaucoma

Disc

Retina



Glaucoma

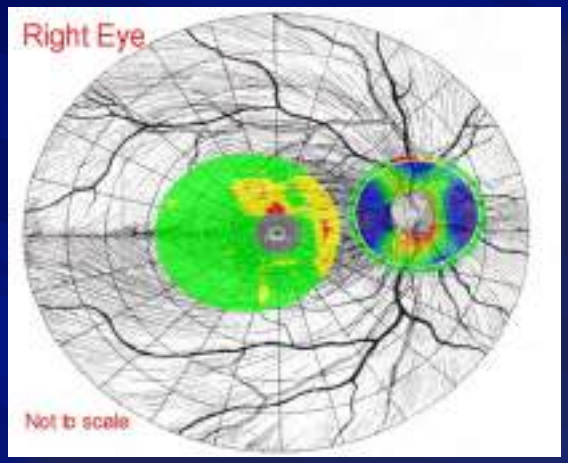
Right Eye
Not to scale

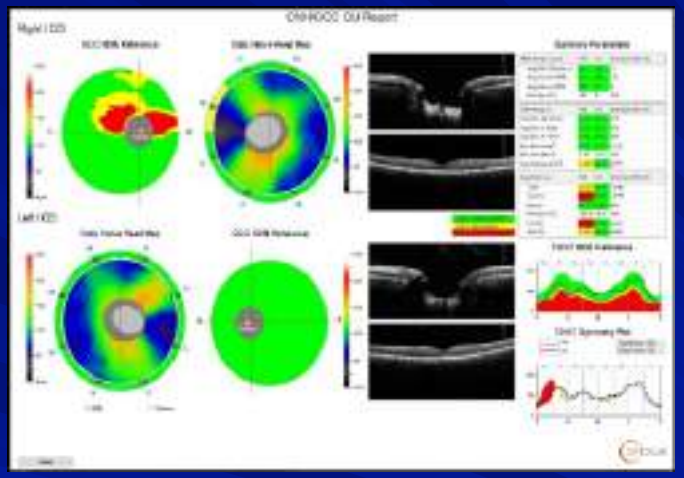

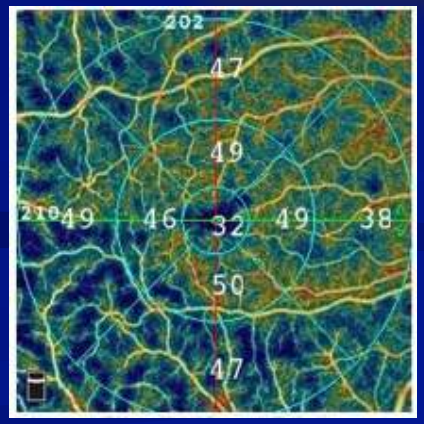
202
47
49
210
49
46
32
49
38
50
47

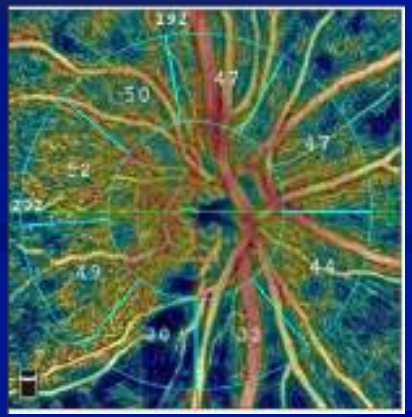
192
47
50
47
52
202
49
44
50
33

How Does OCTA Change the Way You See Glaucoma?

- Shows early changes in the retina and optic disc
- Adds new information to the diagnosis
- Aids in progression detection

Review of Normal 25-year-old man

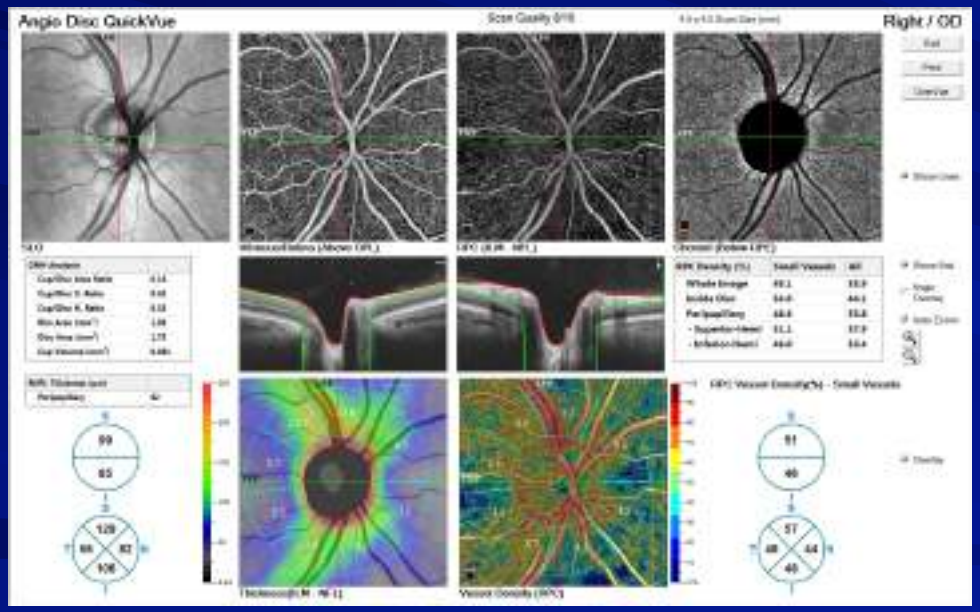

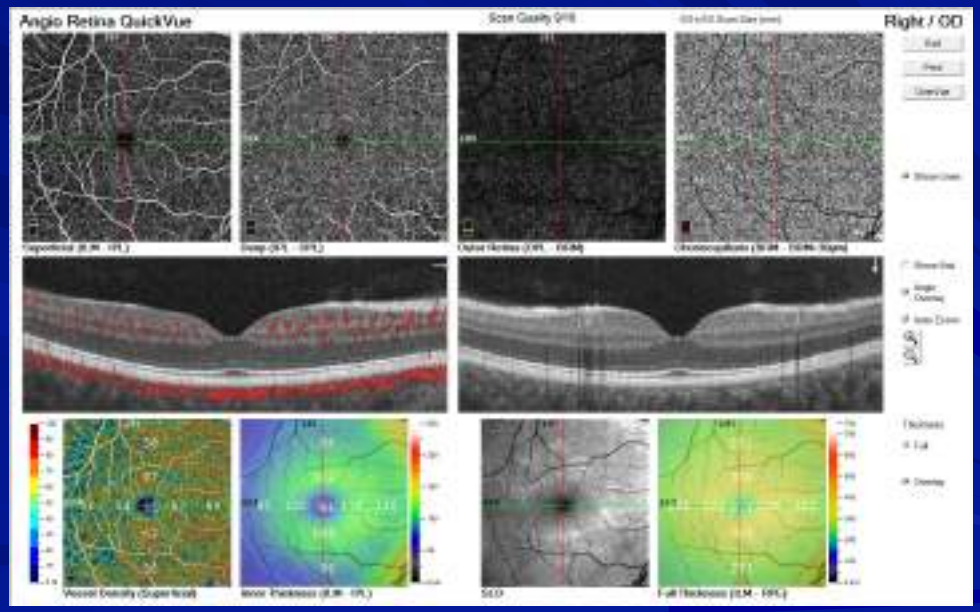

Review of Normal 60-year-old man

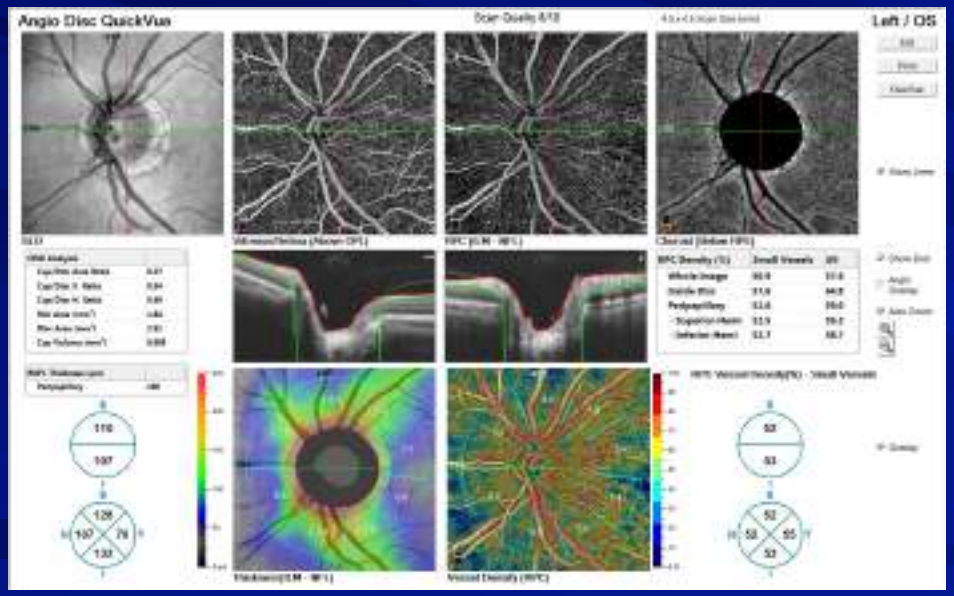

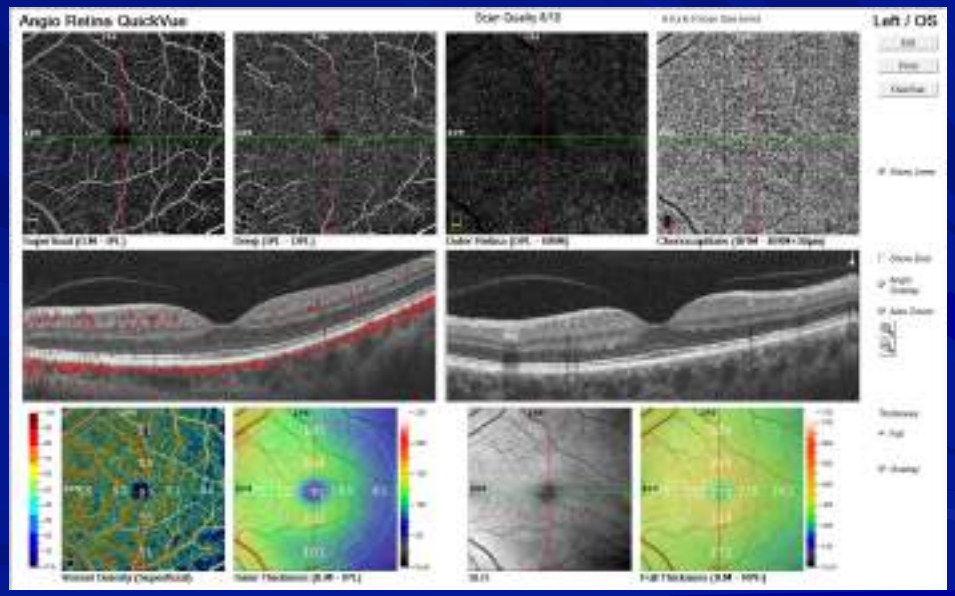

60-Year-Old Montage OD

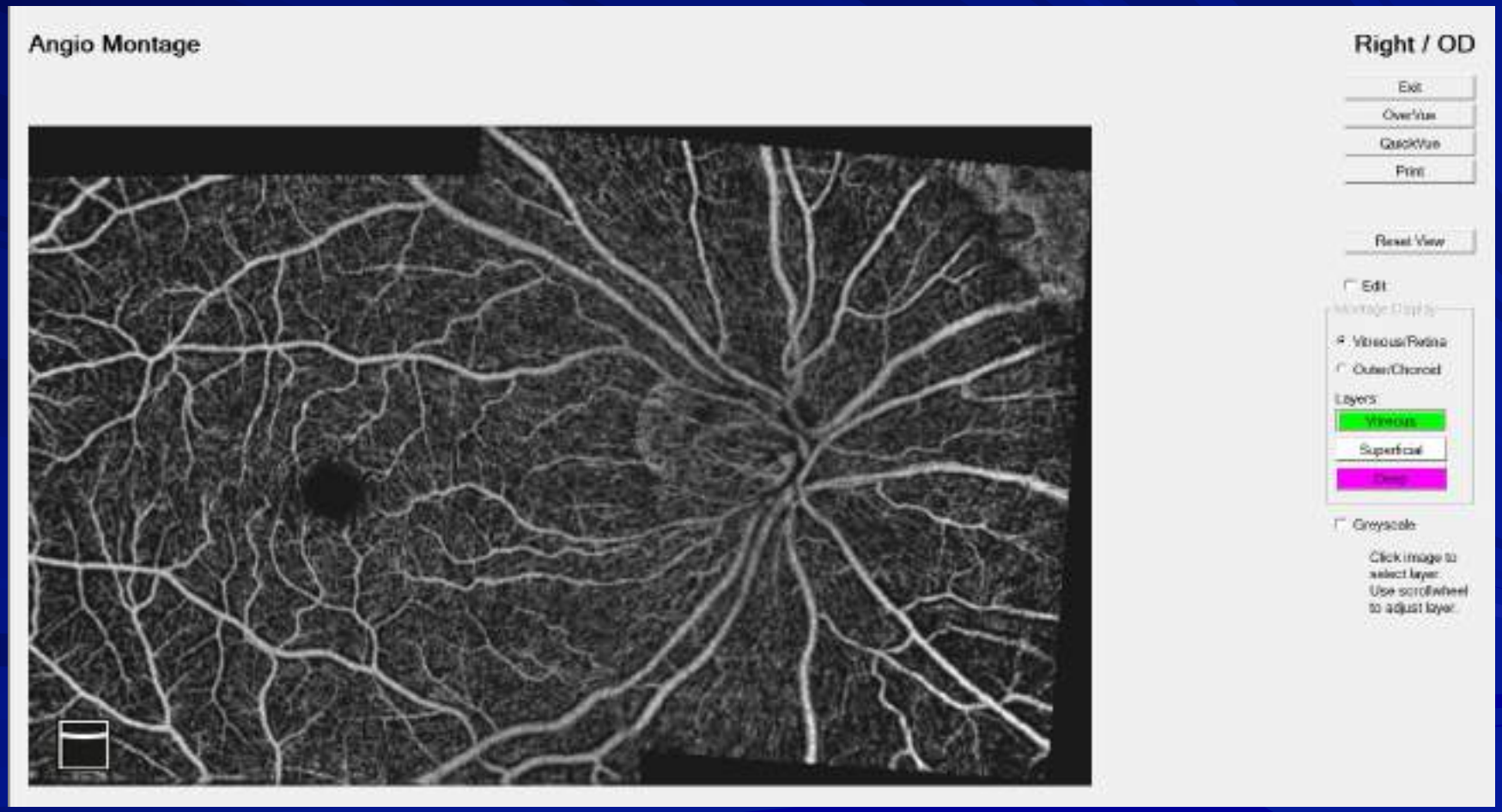

60-Year-Old Montage OS

60-Year-Old Montage OU

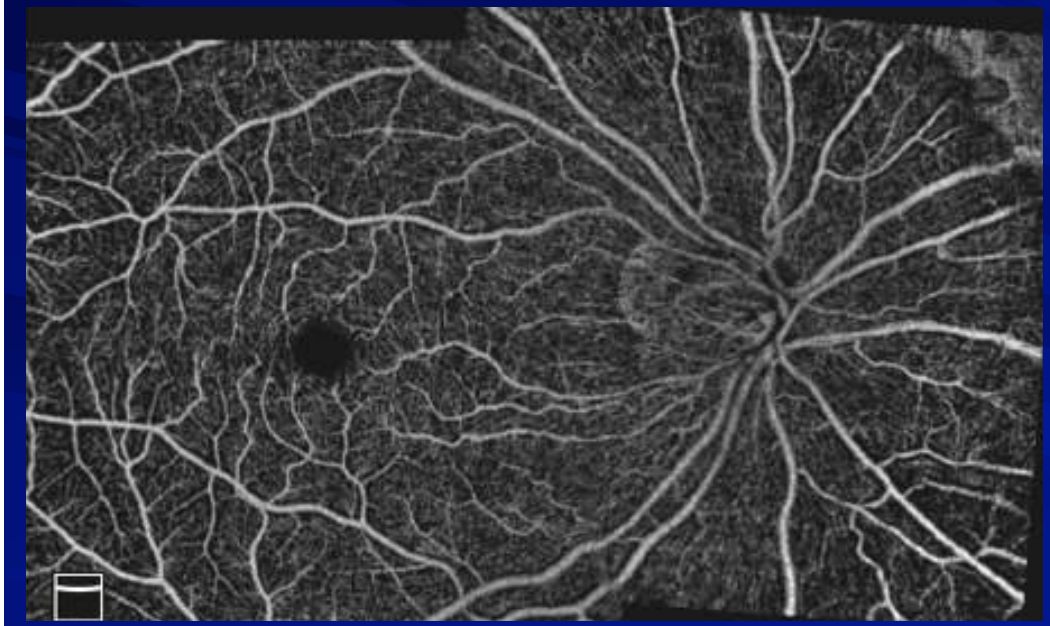

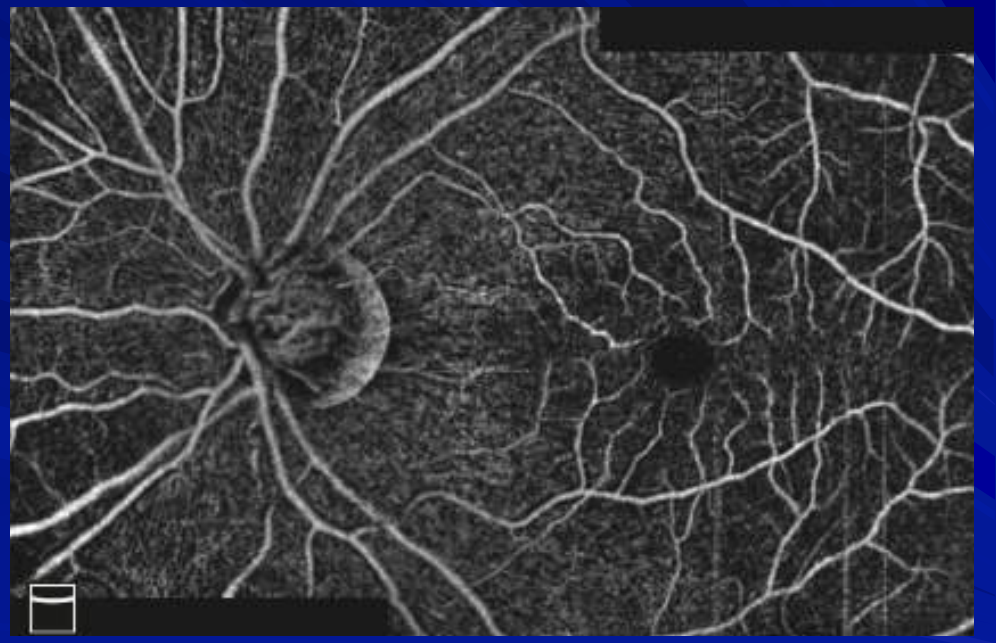

68-year-old woman with glaucoma

- Wants second opinion for glaucoma management
- Recently had cataract surgery OS with iStent
  - September 25, 2017
  - Dorzolamide 2% BID OS, Lumigan 0.01% QD OS
- Our practice recently performed cataract surgery and Kahook dual blade (KDB) MIGS
  - July 24, 2018
- IOP_{GAT}: 12 and 16 at 11:27 am

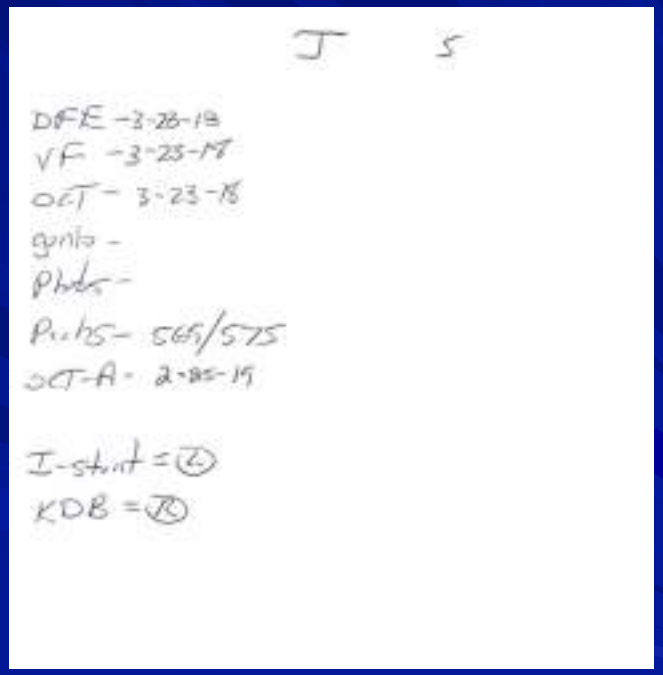

OCT for Pachymetry in Glaucoma

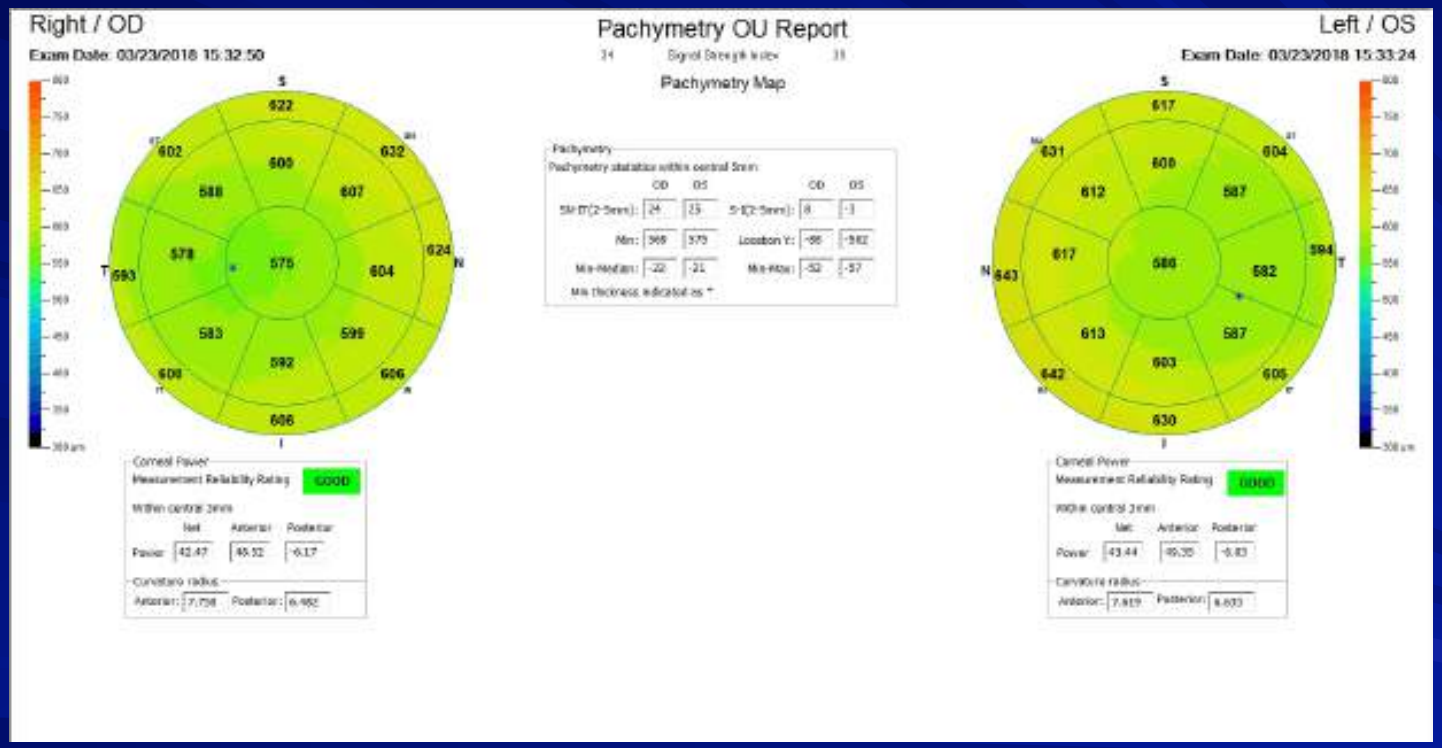

OCT GCC and NFL

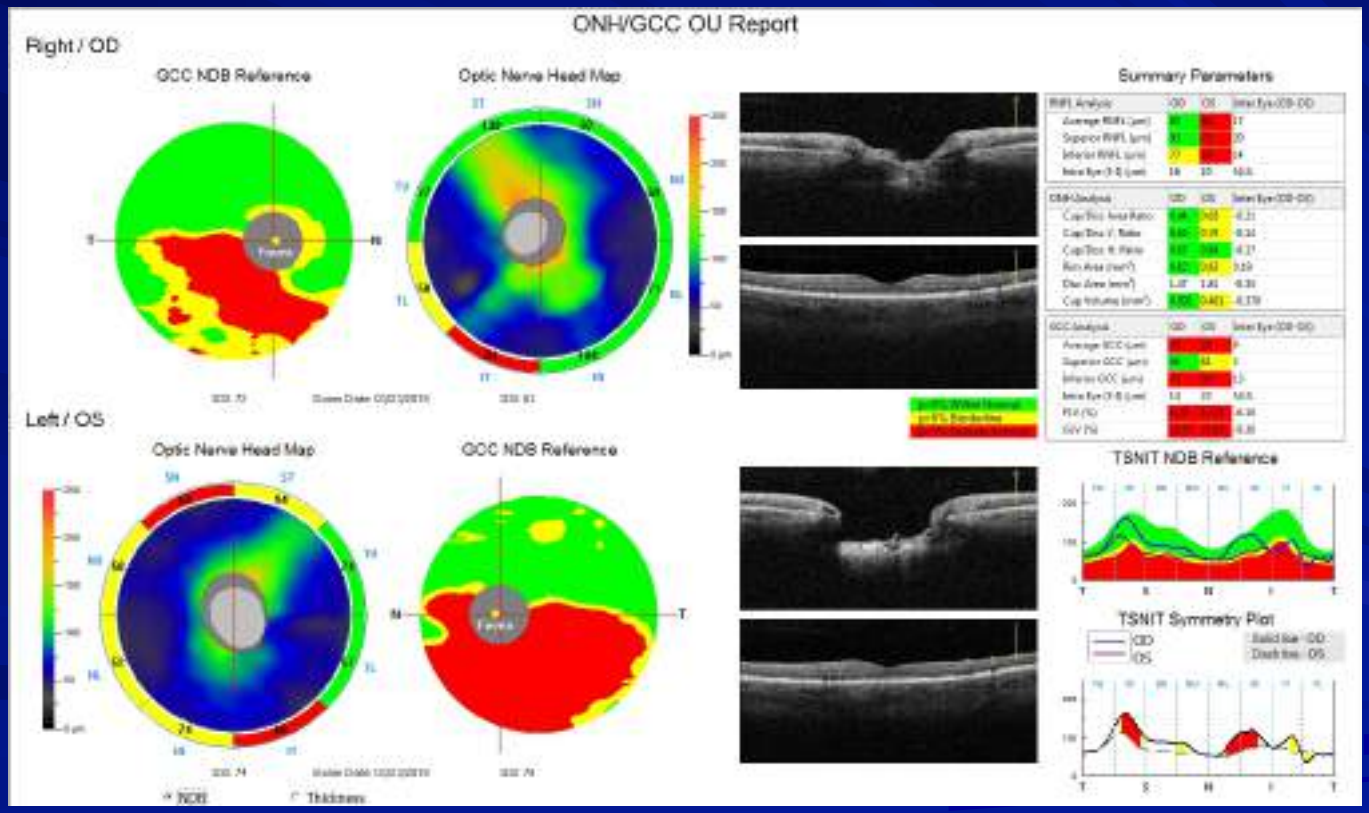

Visual Fields

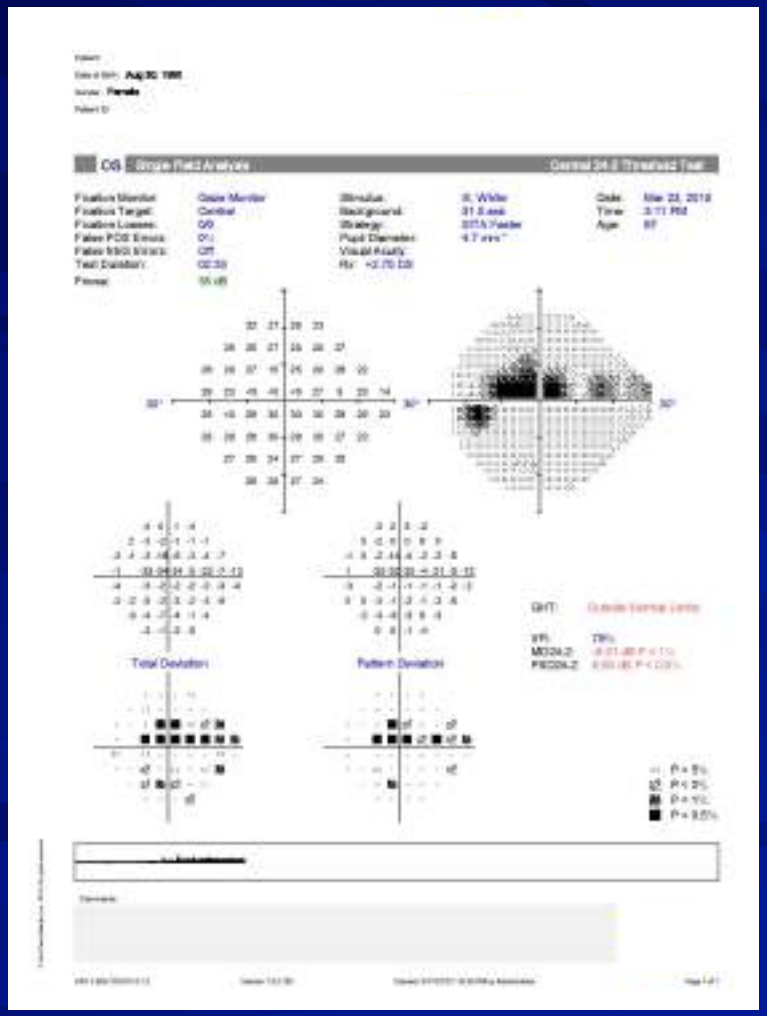



Angiography and AngioAnalytics of Disc

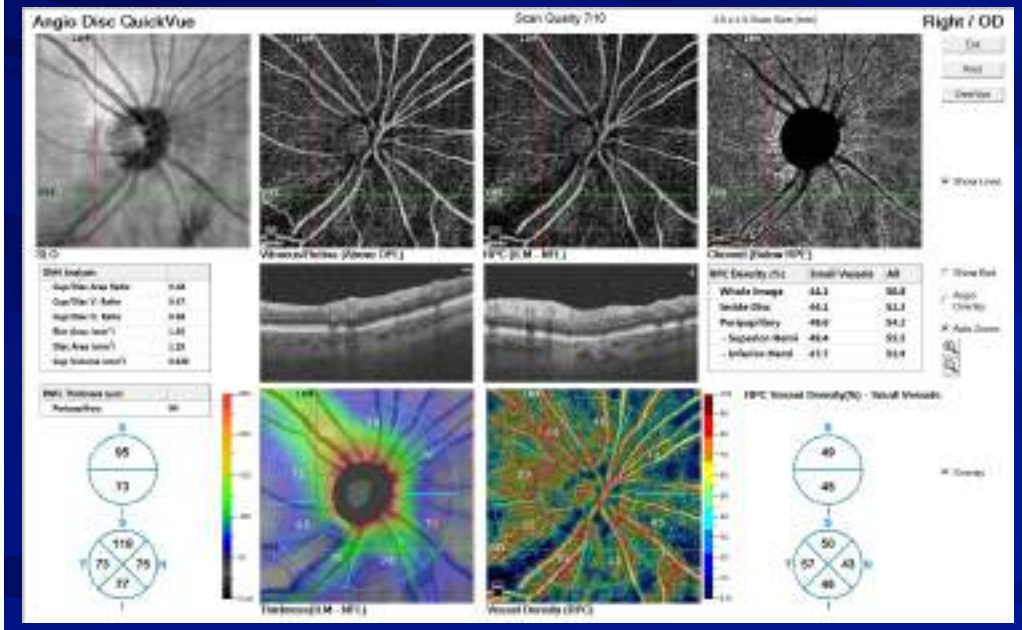

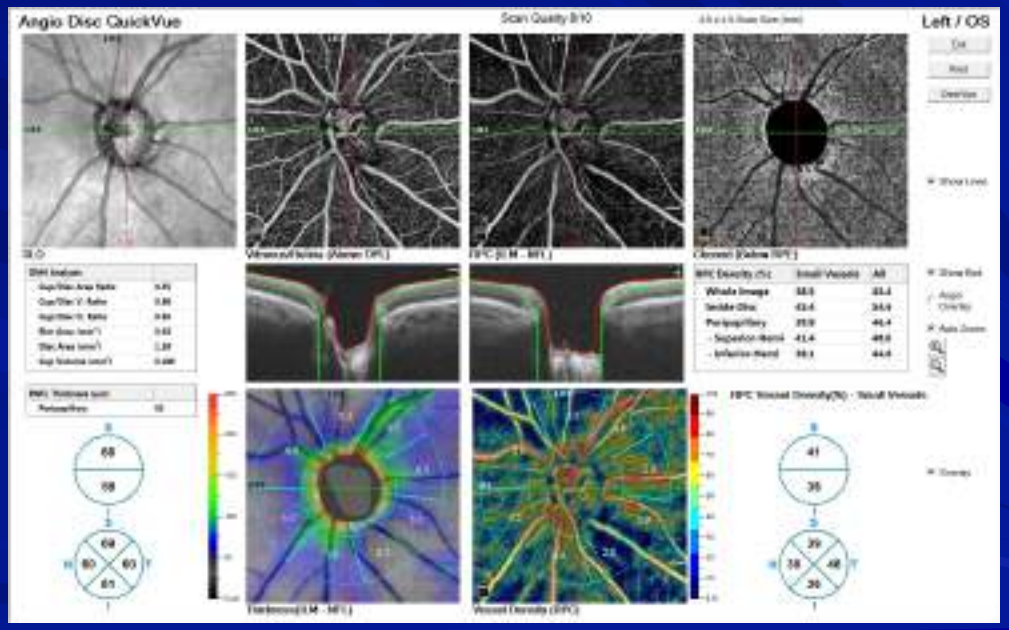

En Face Radial Peripapillary Capillaries (RPC)

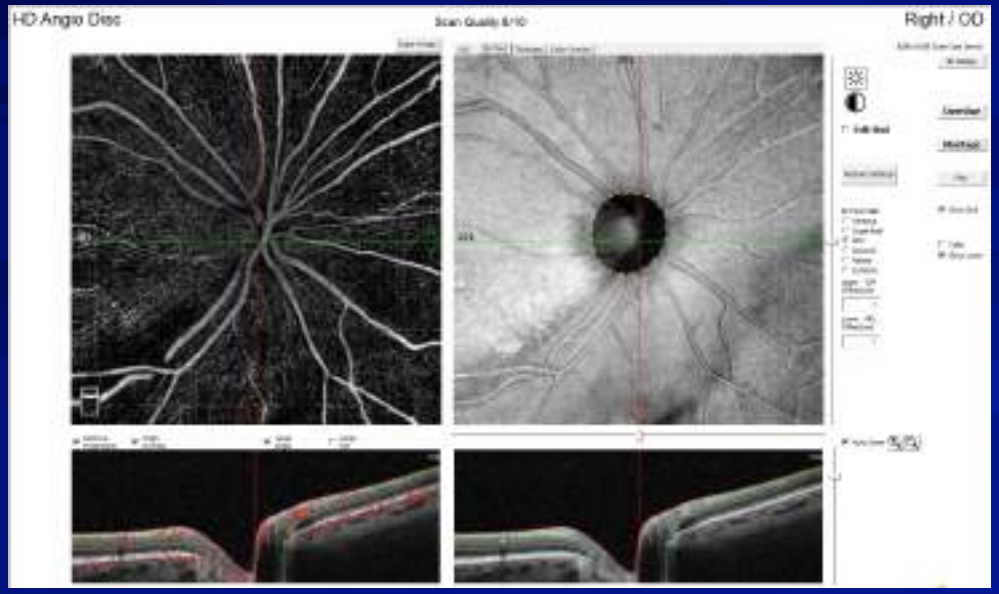

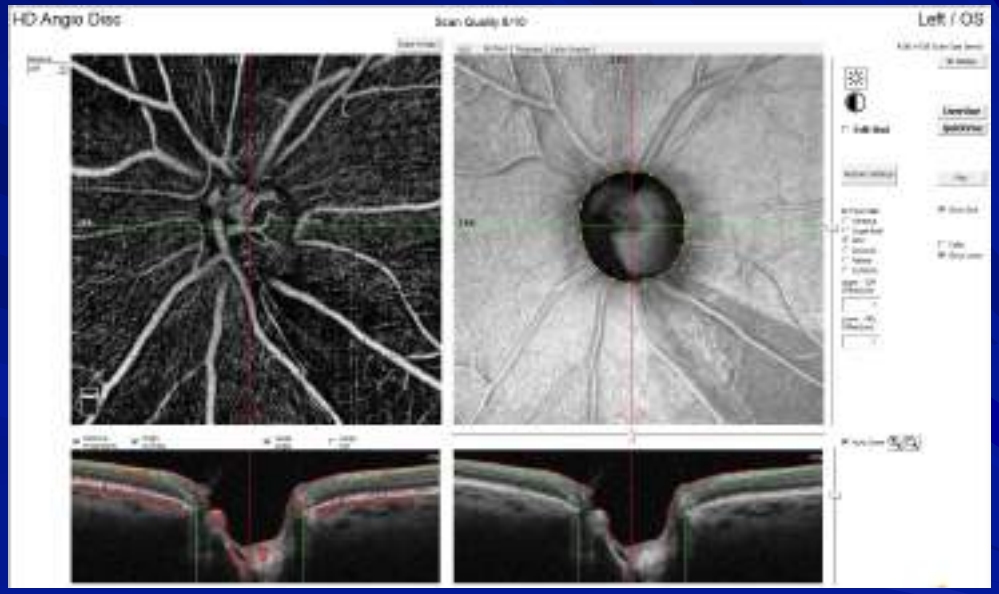

Angiography and AngioAnalytics of Retina

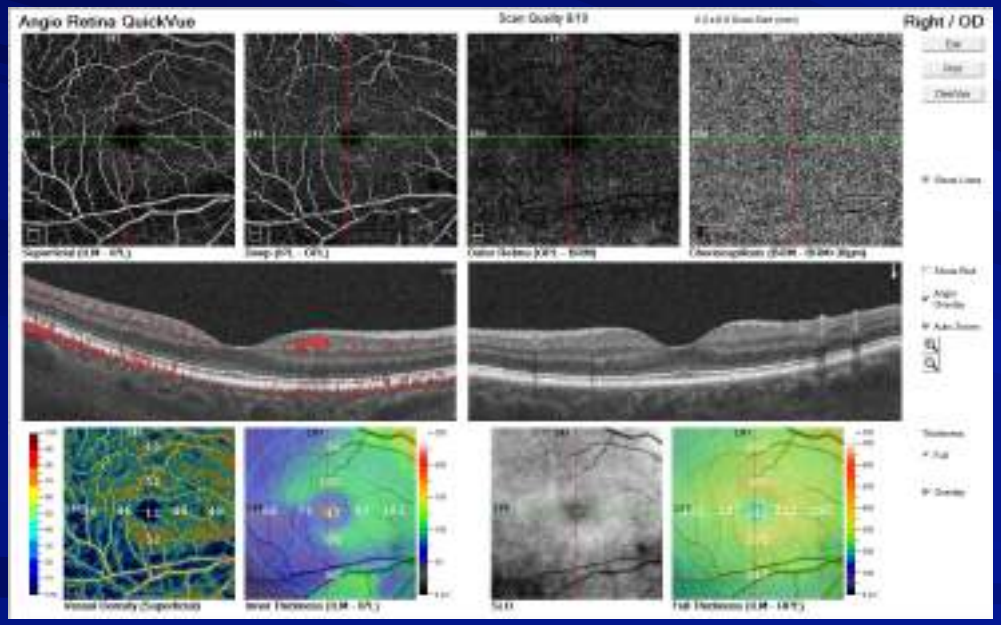

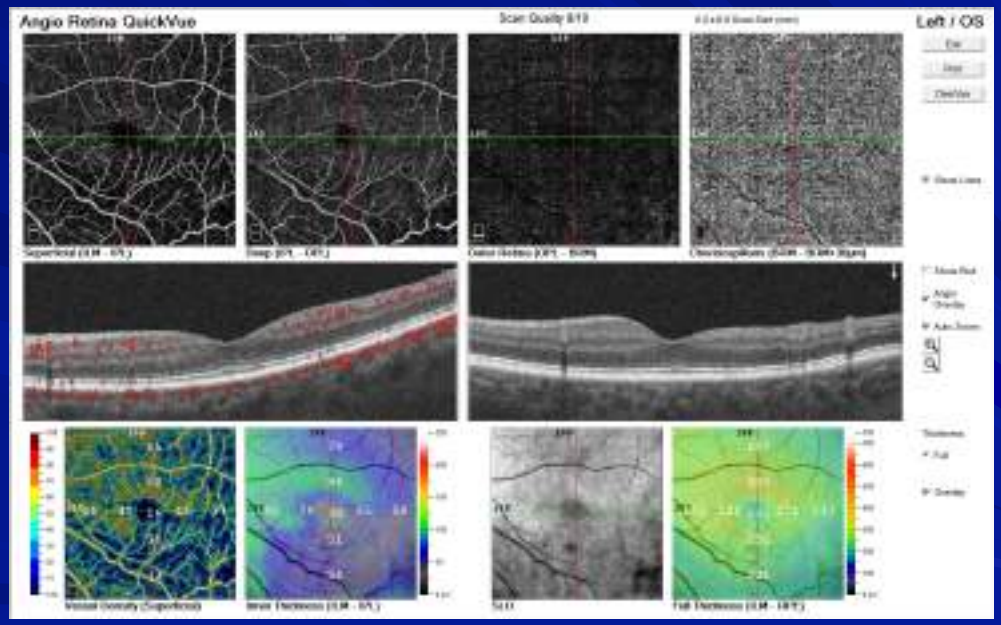

Montage OD

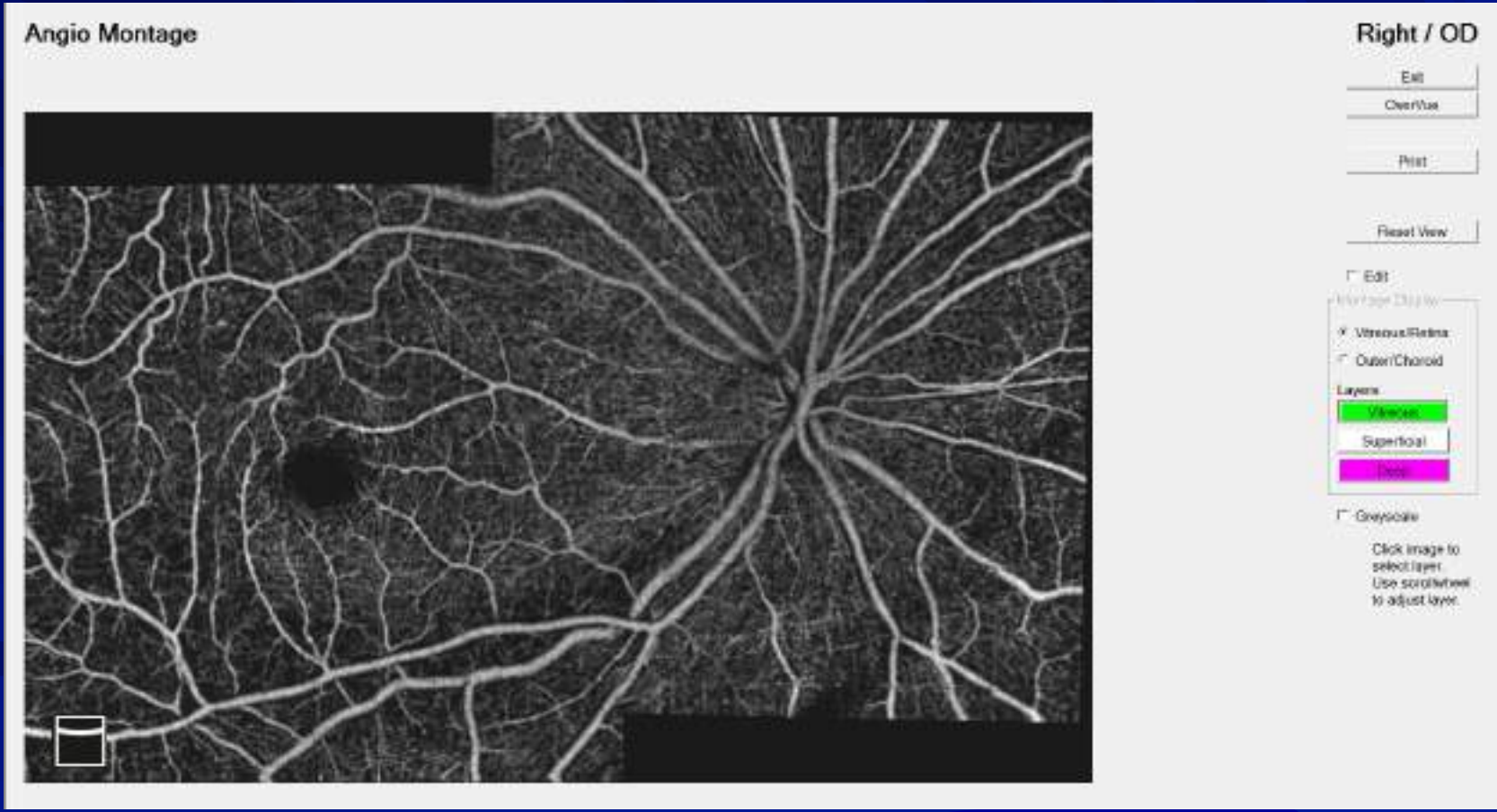
Angio Montage
Right / OD
Exit
Print
Reset View
Edit
Vitreous/Retina
Outer/Choroid
Layers
Superficial
Greyscale
Click image to select layer.
Use scrollwheel to adjust layer.

Montage OS


Angio Montage
Left / OS
Exit
Overlay
QuickVue
Print
Reset View
Edit
Vitreous/Retina
Outer/Choroid
Layers:
Vitreous
Superficial
Deep
Greyscale
Click image to select layer
Use scrollwheel to adjust layer

Montage OU

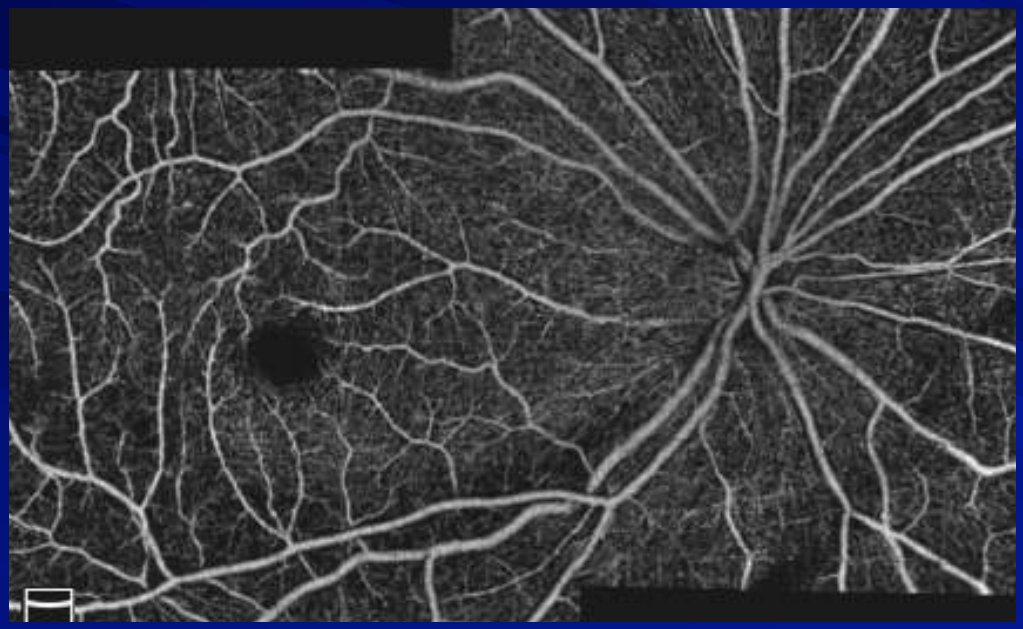

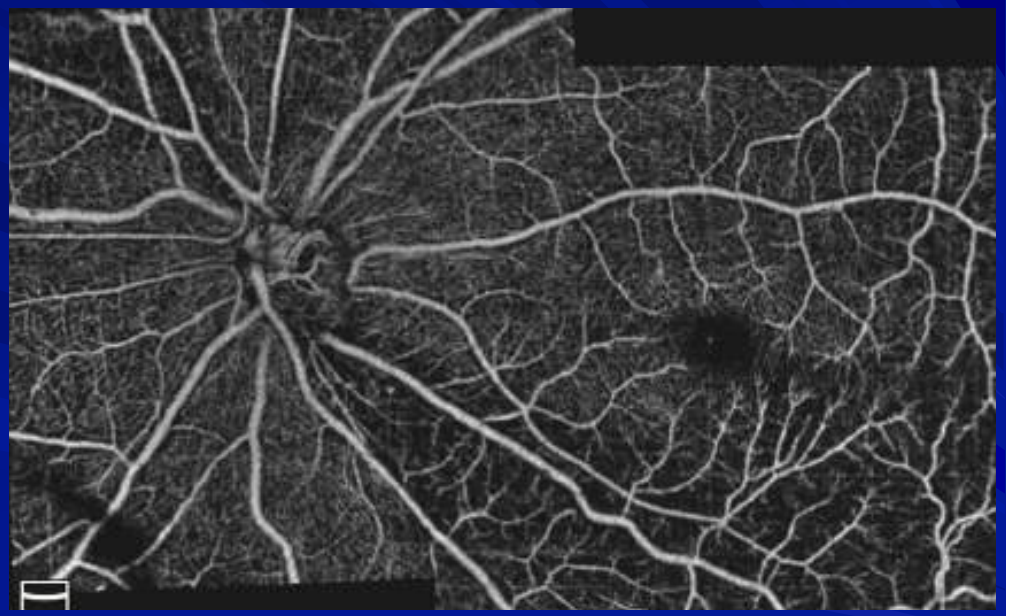

74-year-old man

- POAG, OS > OD
- Lumigan 0.01% QD OU
- Combigan BID OU

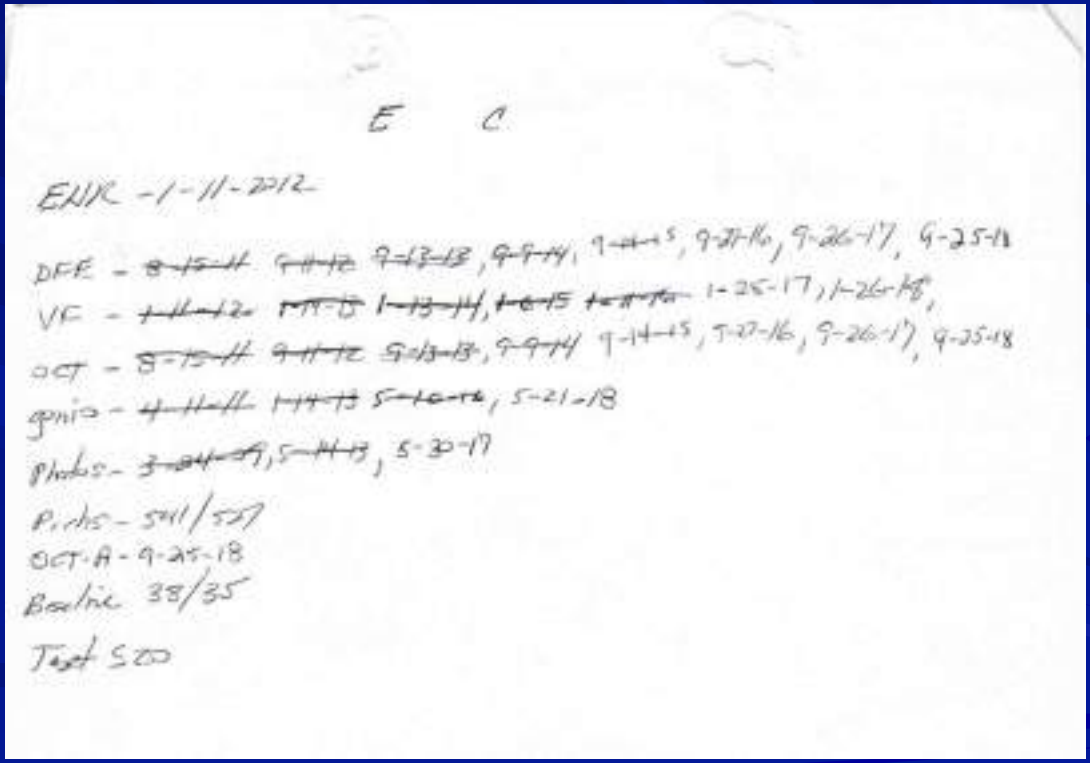

VF OD and OS 1-26-2018





VF OD and OS GPA 1-26-2018





OCT NFL and GCC 9-25-2018

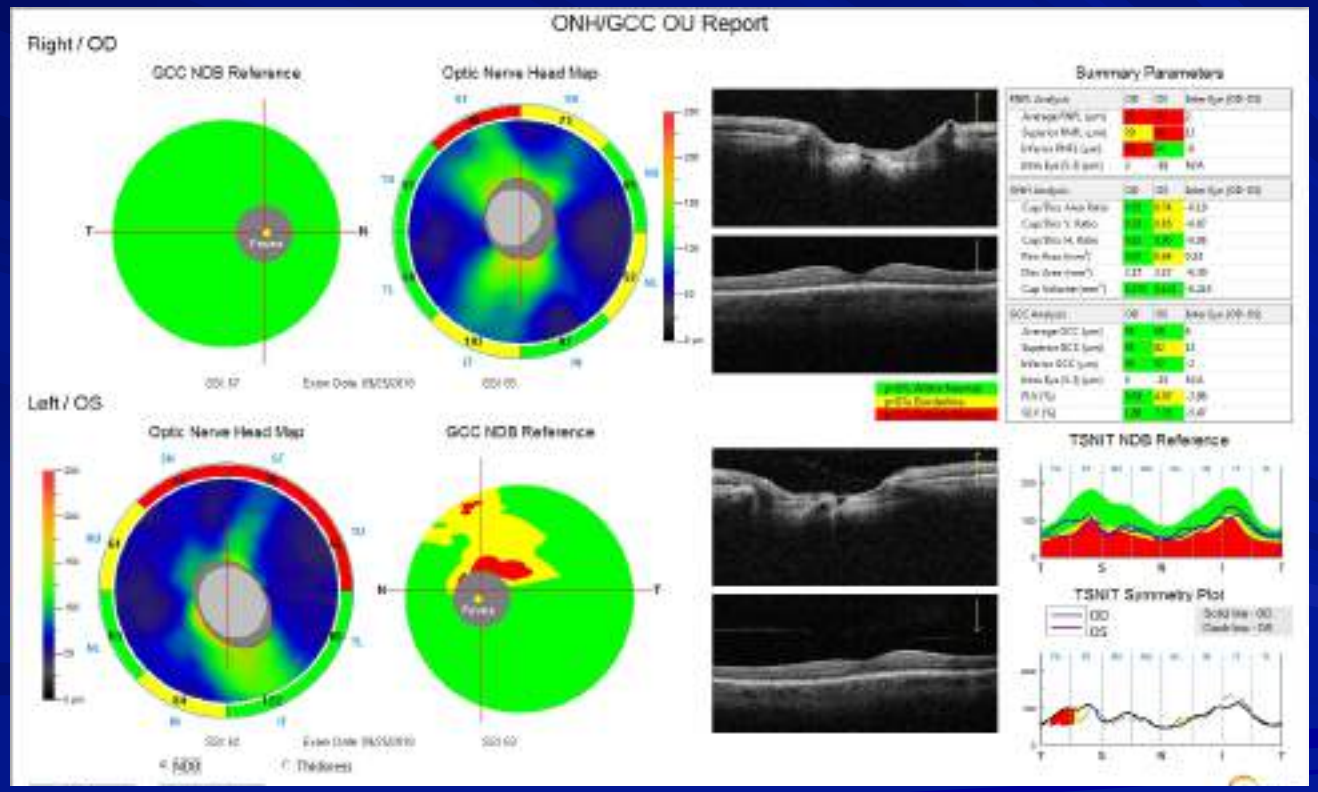

Change Analysis NFL-GCC

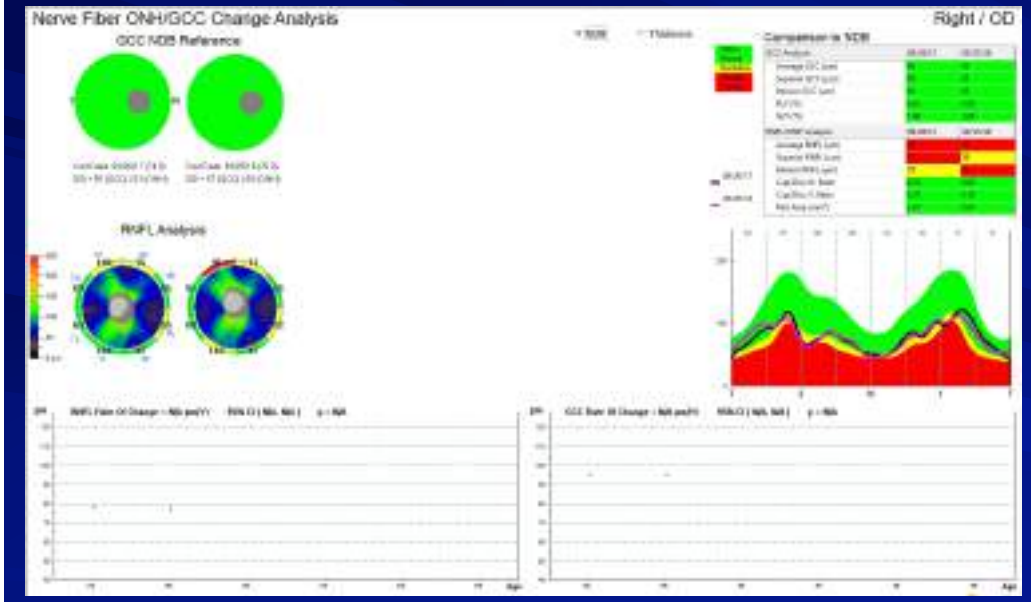

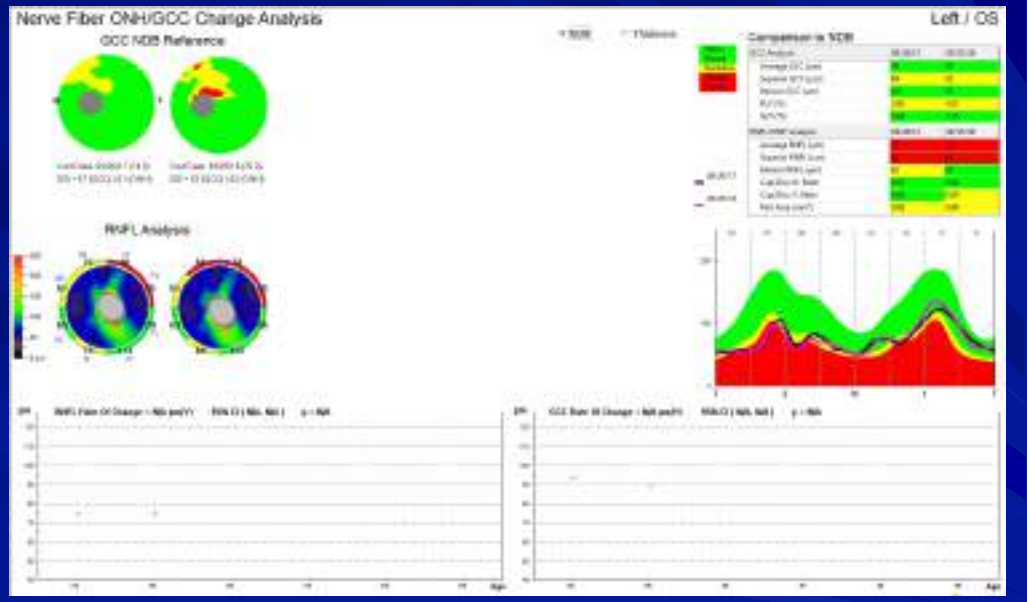

OCT-A 9-25-2018
POAG OS > OD

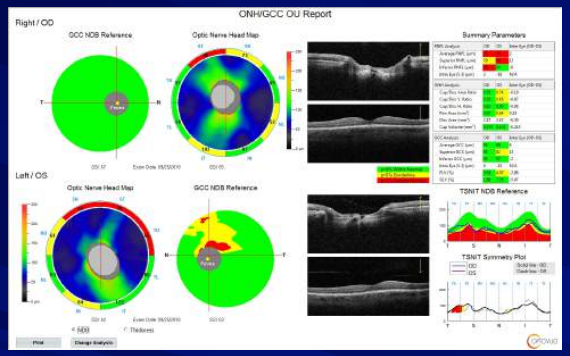

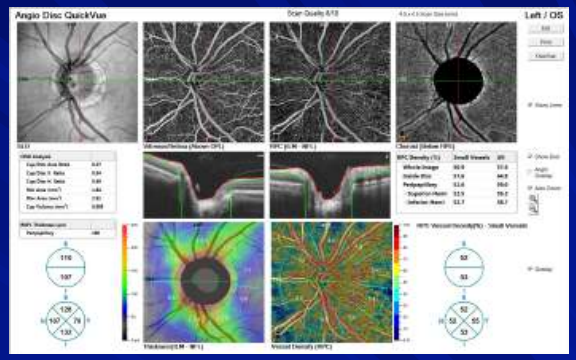

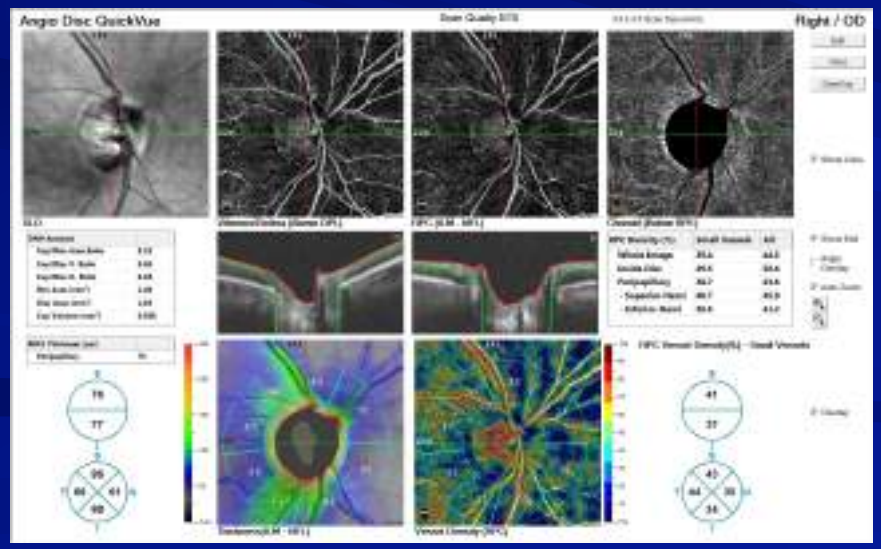

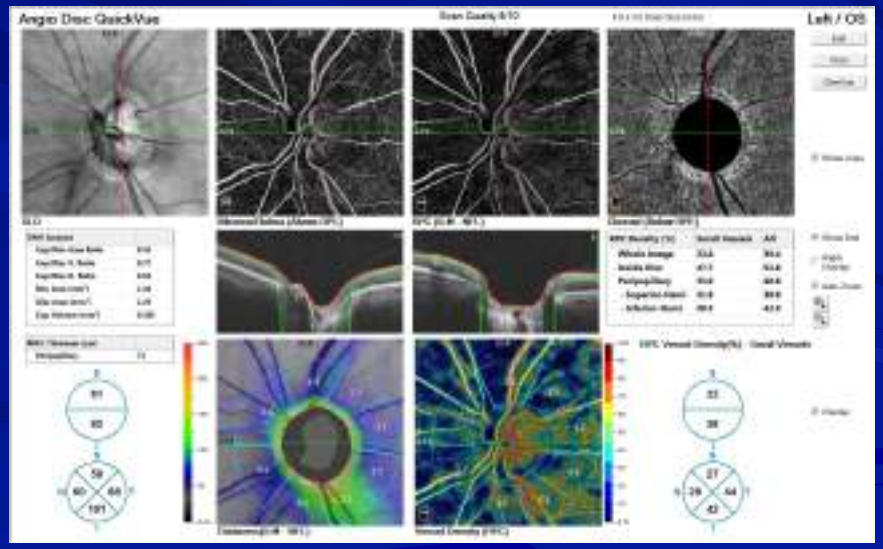

OCT-A 9-25-2018
POAG OS > OD

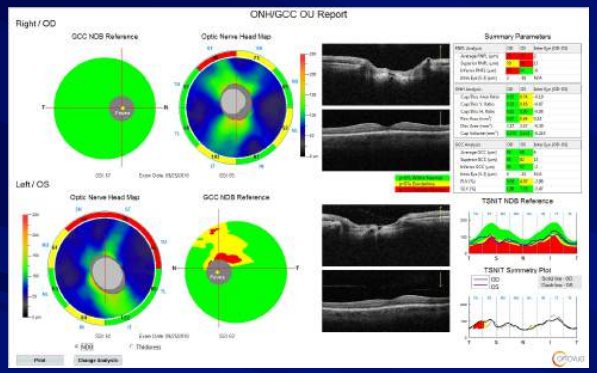

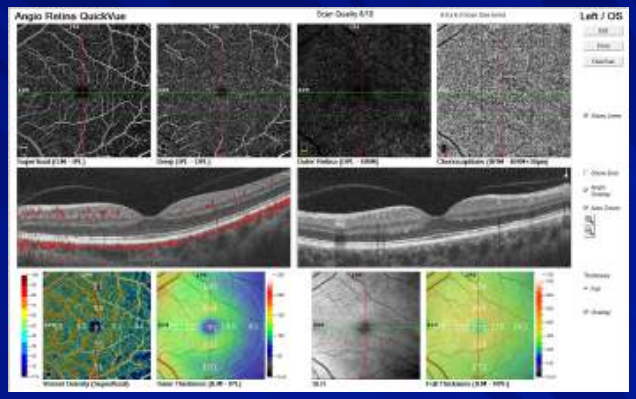

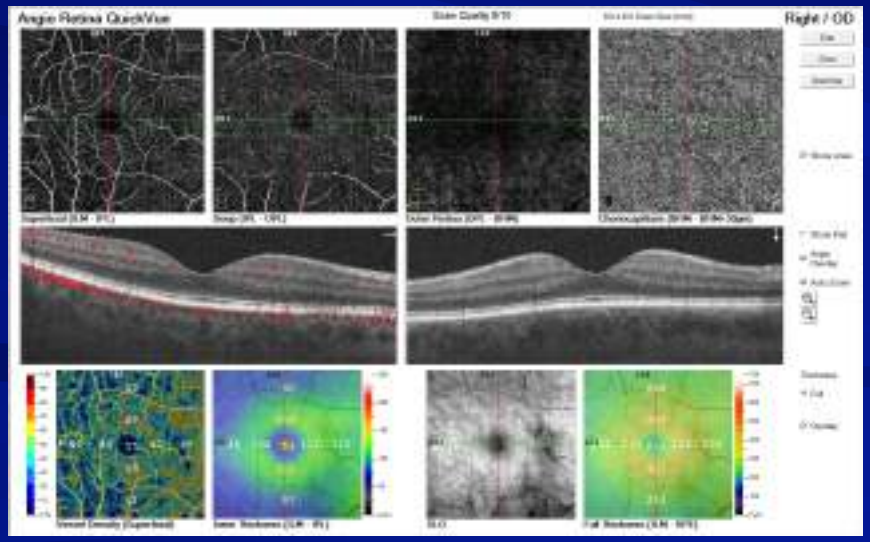

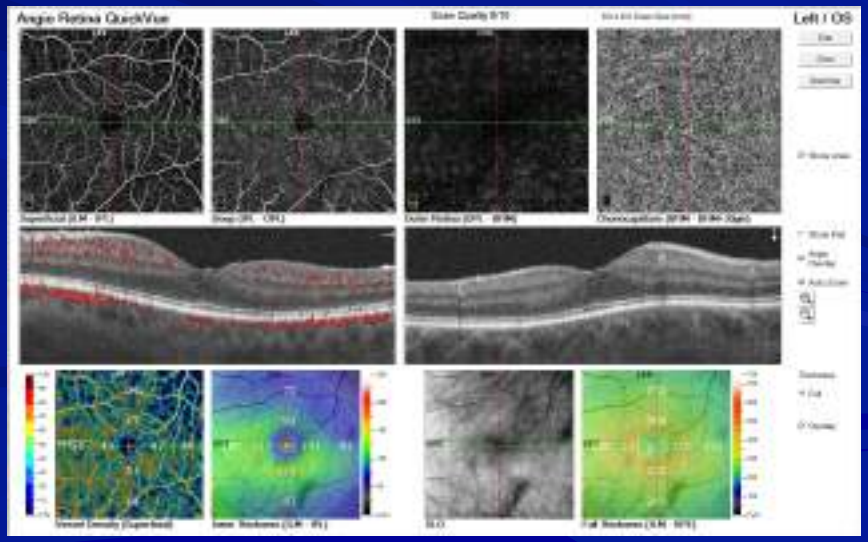

Montage OD


Angio Montage
Right / OD
Exit
Print
Reset View
Edit
Vitreous/Retina
Outer/Choroid
Layers
Superficial
Greyscale
Click image to select layer. Use scrollwheel to adjust layer.

Montage OS

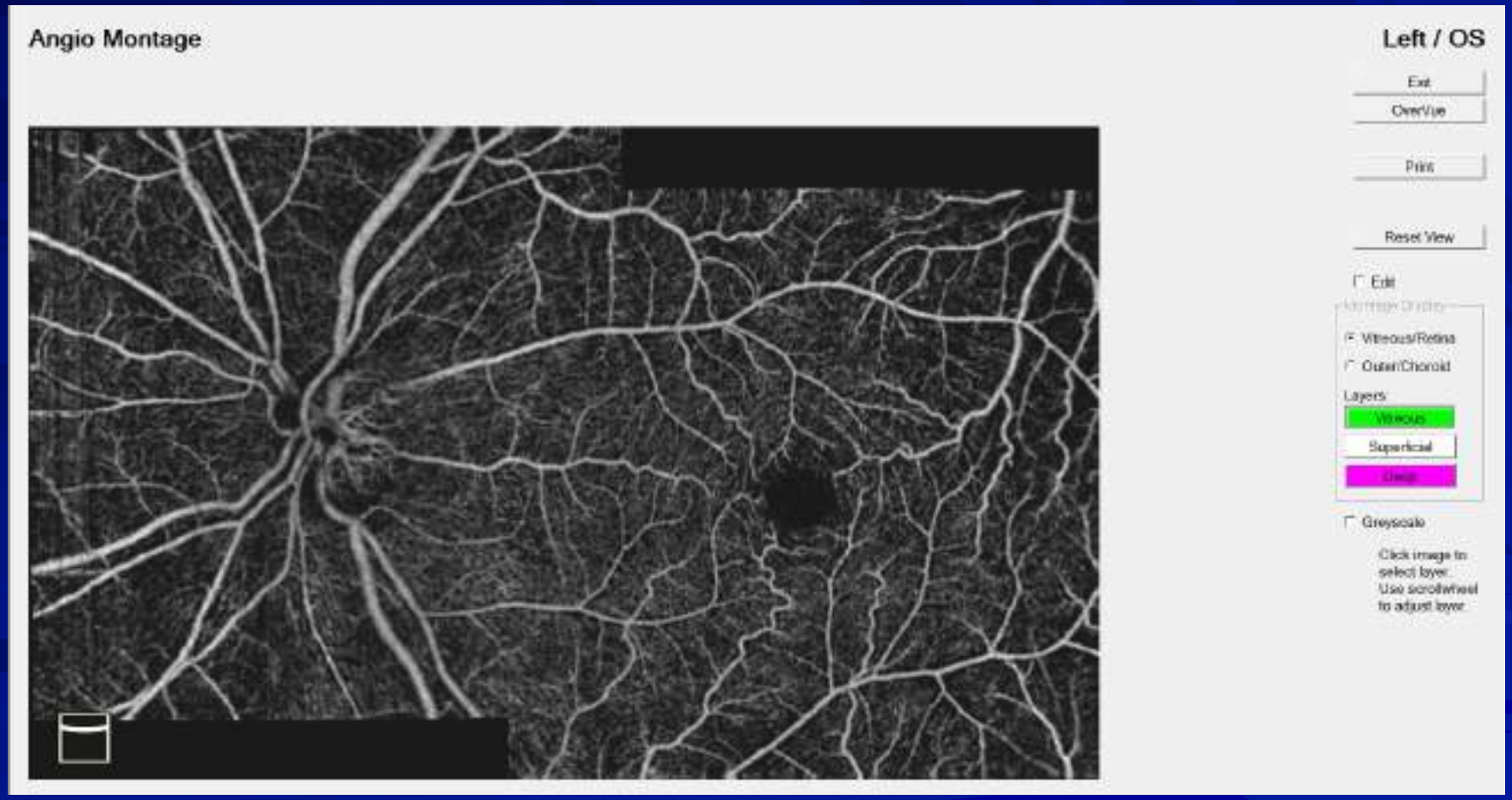
Angio Montage
Left / OS
Exit
OverVue
Print
Reset View
Edit
Vitreous/Retina
Outer/Choroid
Layers
Vitreous
Superficial
Deep
Greyscale
Click image to select layer. Use scrollwheel to adjust layer.

Montage OU

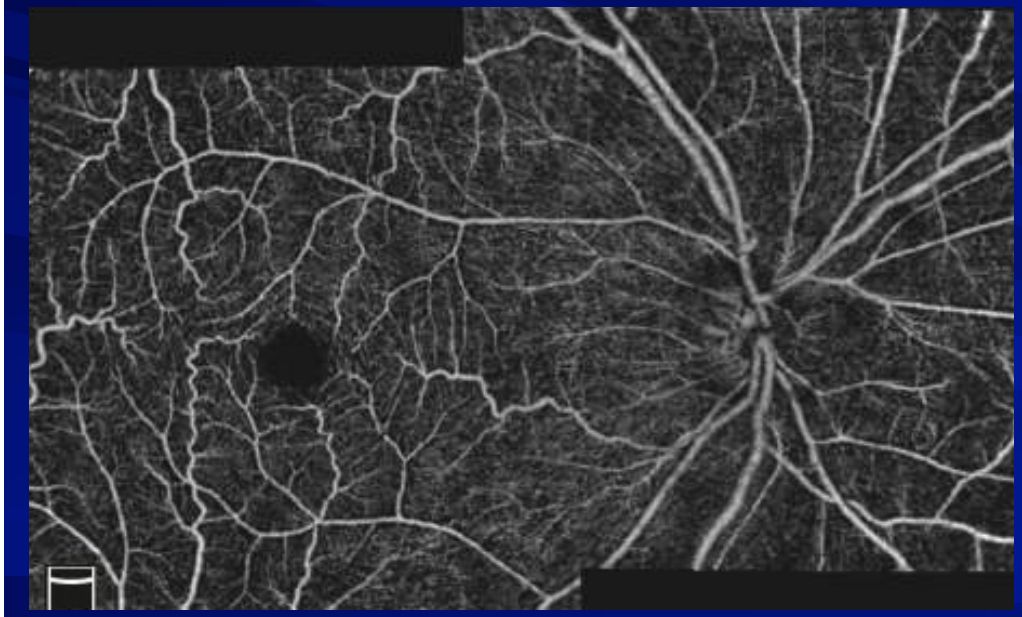

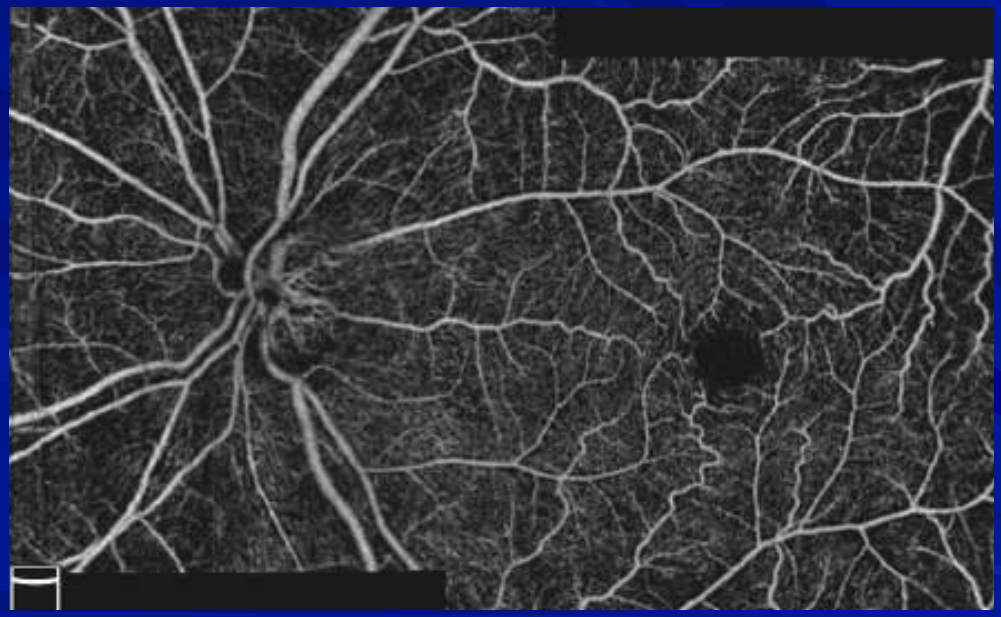

They do read their EHR communication

Drs. Centar & Imler

From:
Date: Tuesday, September 25, 2018 1:07 PM
To: <centarimler@atlanticbb.net>
Subject:

To Whom it may concern:

I was reading my patient chart online, which was emailed to me right after my office visit today. I noticed they have my weight recorded as 344 pounds. That weight is incorrect because I'm now at 333, which has been holding steady between 332 and 334 for several months now.

Sincerely,

Sent from my iPhone=

49 year old man

- Ocular Hypertension since 2014
  - No treatment
- Pigment Dispersion
- Baseline IOP or Tmax 26/26
  - 2014— March 2018
- Today 30/32, new Tmax 9-25-18

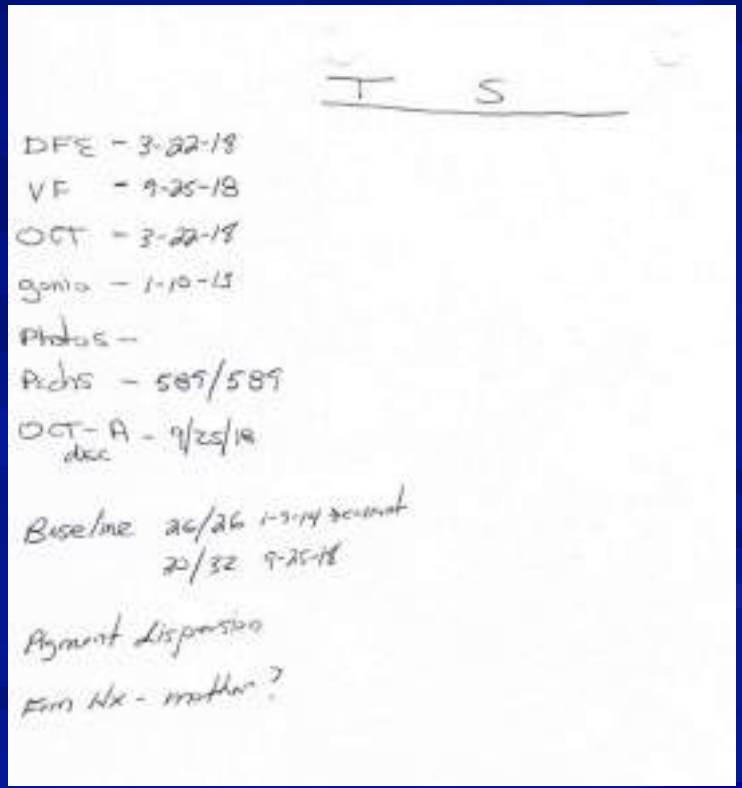

T S

DFE - 3-22-18
VF - 9-25-18
OCT - 3-22-18
gonio - 1-10-13
Photos -
Pachs - 589/589
OCT-A - 9/25/18
disc

Baseline 26/26 1-3-14 accurate
20/32 9-25-18

Pigment dispersion
Fam Hx - mother?

VF 24-2 Sita-Faster
9-25-2018





OCT NFL and GCC
3-22-18

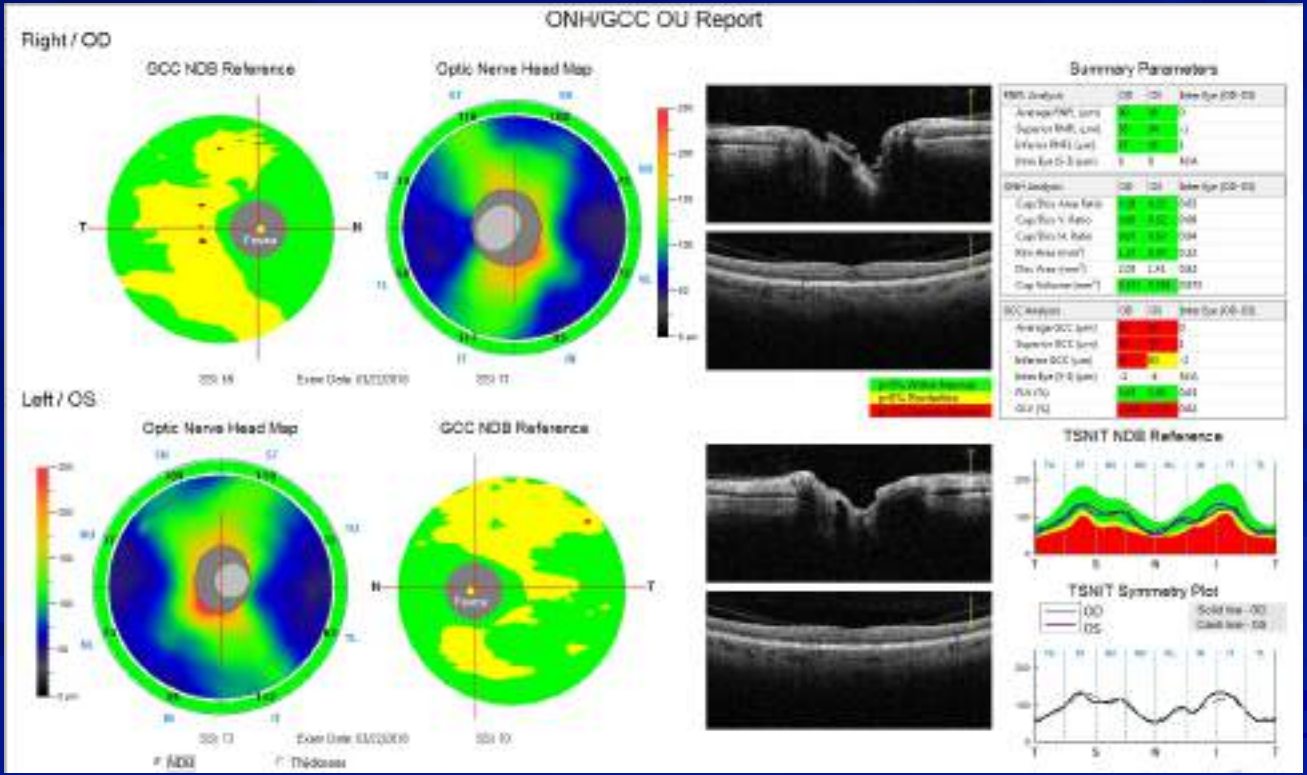

OCT-A 9-25-2018

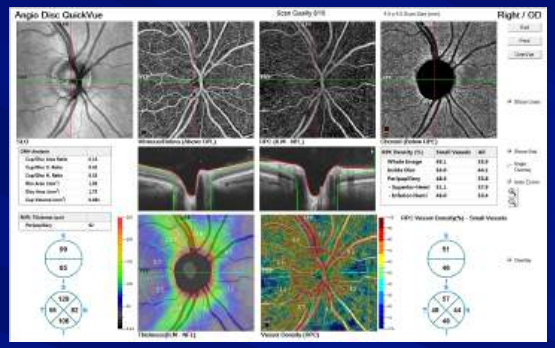

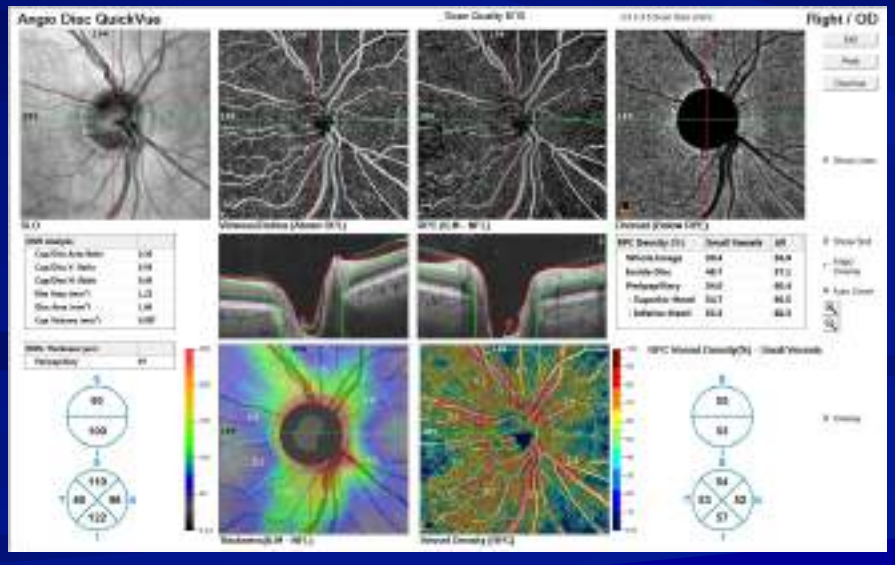

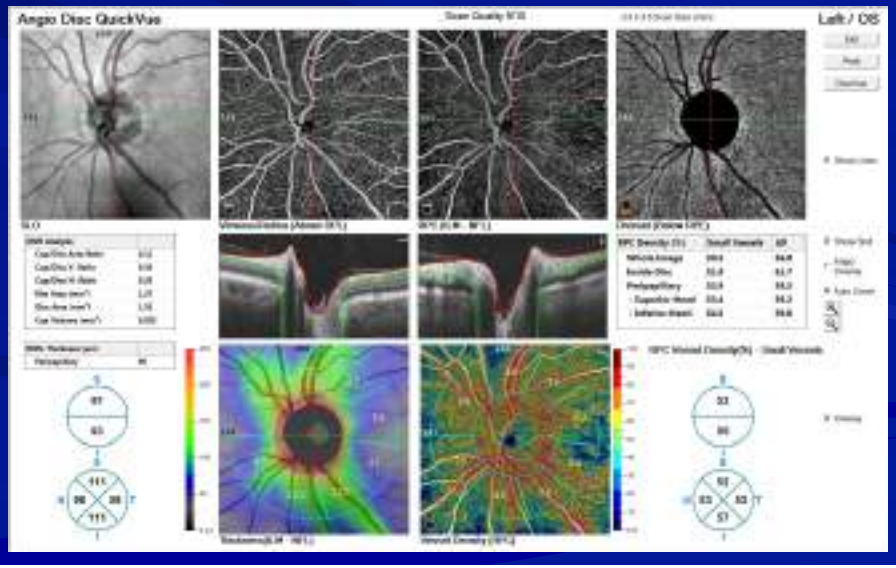

OCT-A 9-25-2018

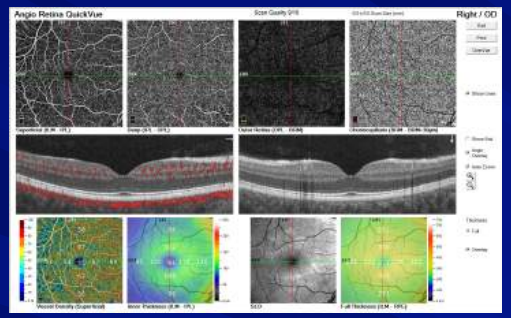

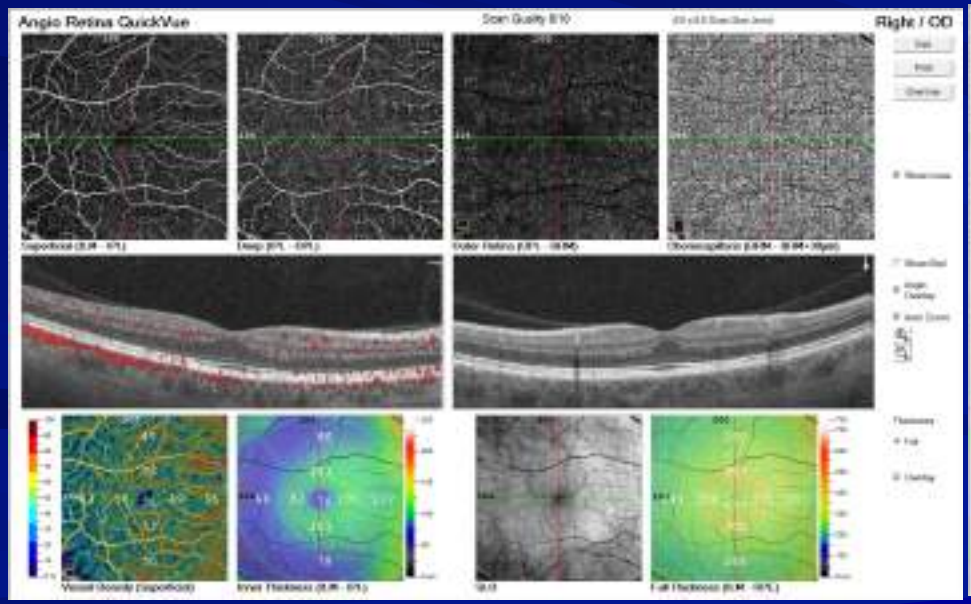

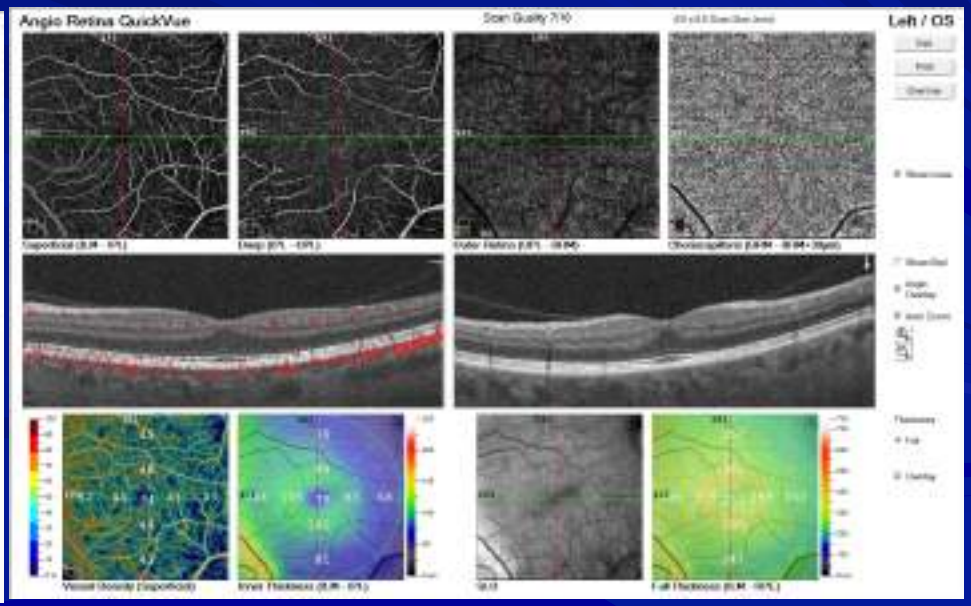

Montage OD


Angio Montage
Right / OD
Exit
Overlay
Print
Reset View
Edit
Vitreous/Retina
Outer/Choroid
Grayscale
Click image to select layer. Use scrollwheel to adjust layer.

Montage OS

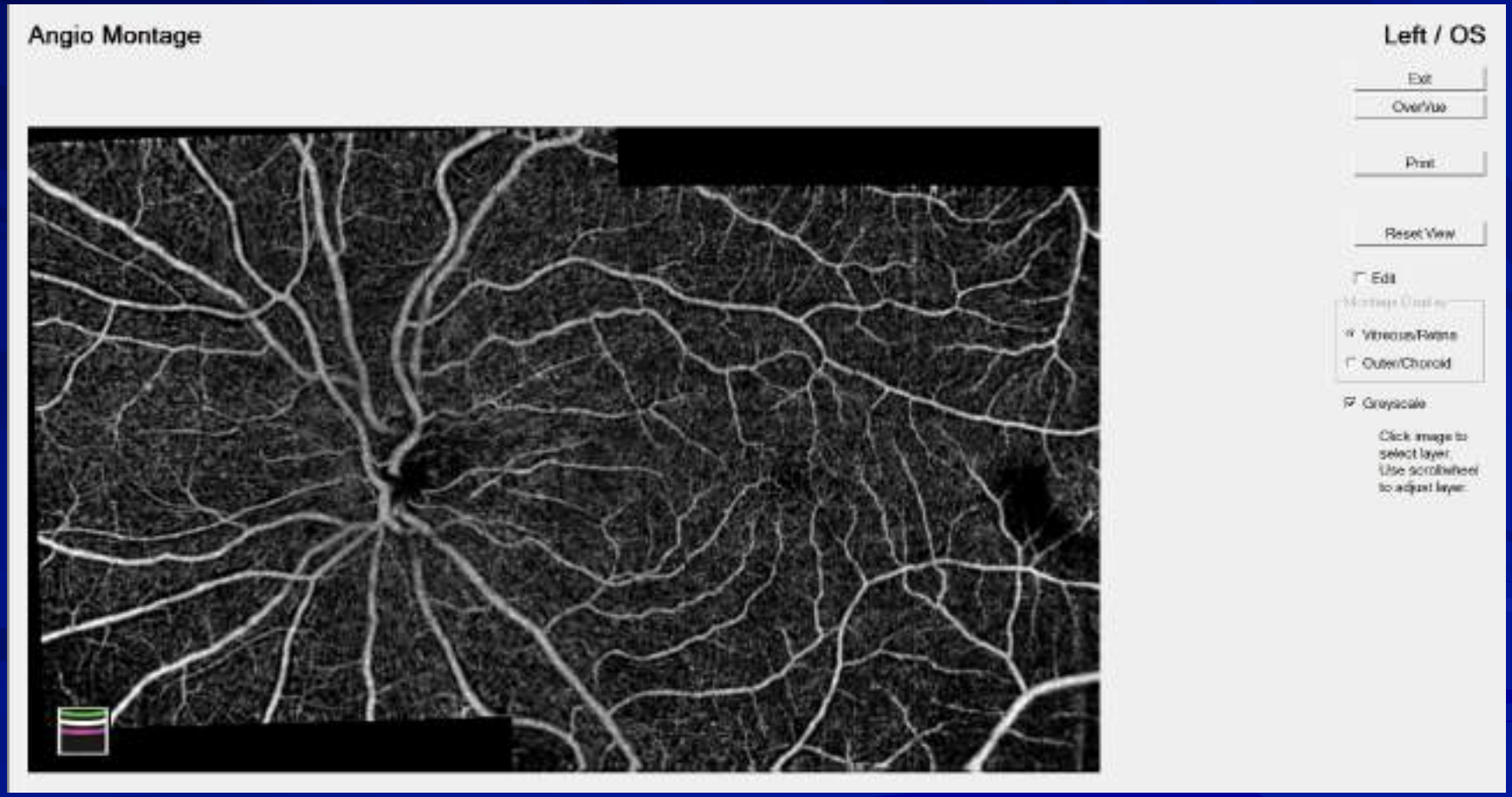
Angio Montage
Left / OS
Exit
Overlay
Print
Reset View
Edit
Vitreous/Retina
Outer/Choroid
Grayscale
Click image to select layer. Use scrollwheel to adjust layer.

Montage OU

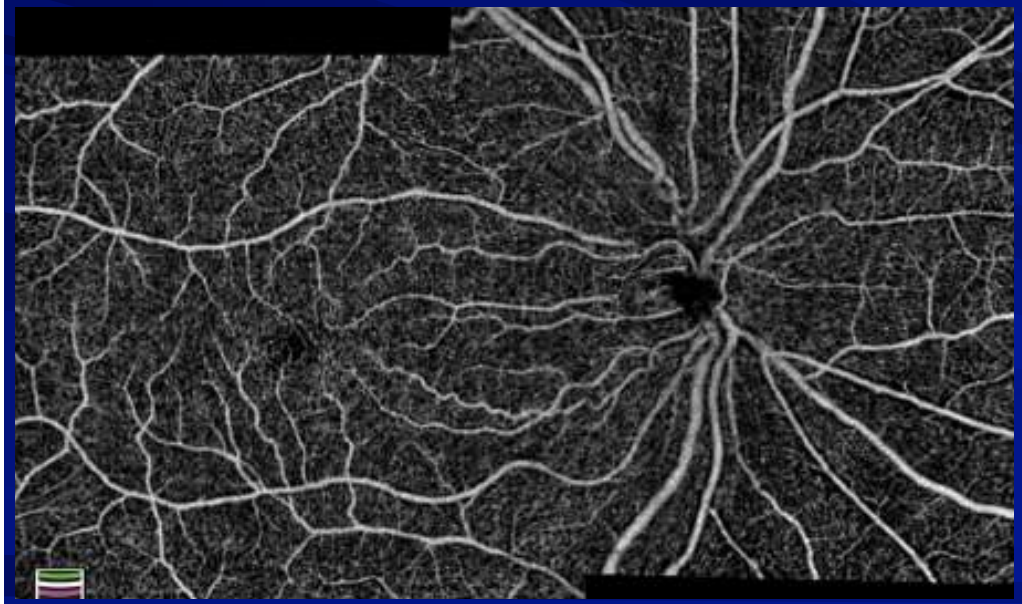

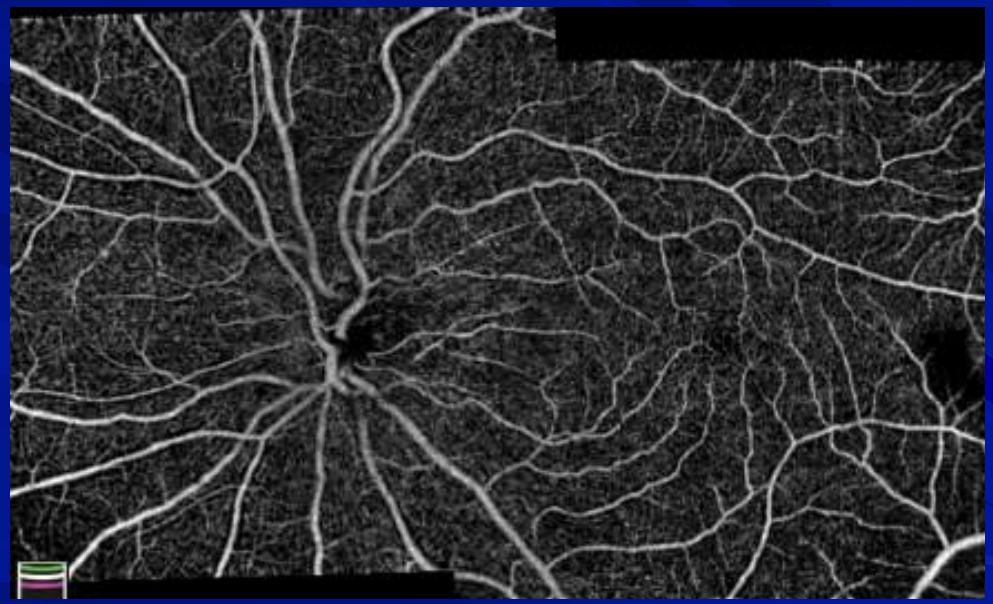

How Does OCTA Change the Way You See Glaucoma?

- Shows early changes in the retina and optic disc
- Adds new information to the diagnosis
- Aids in progression detection

Glaucoma versus Other Optic Neuropathy

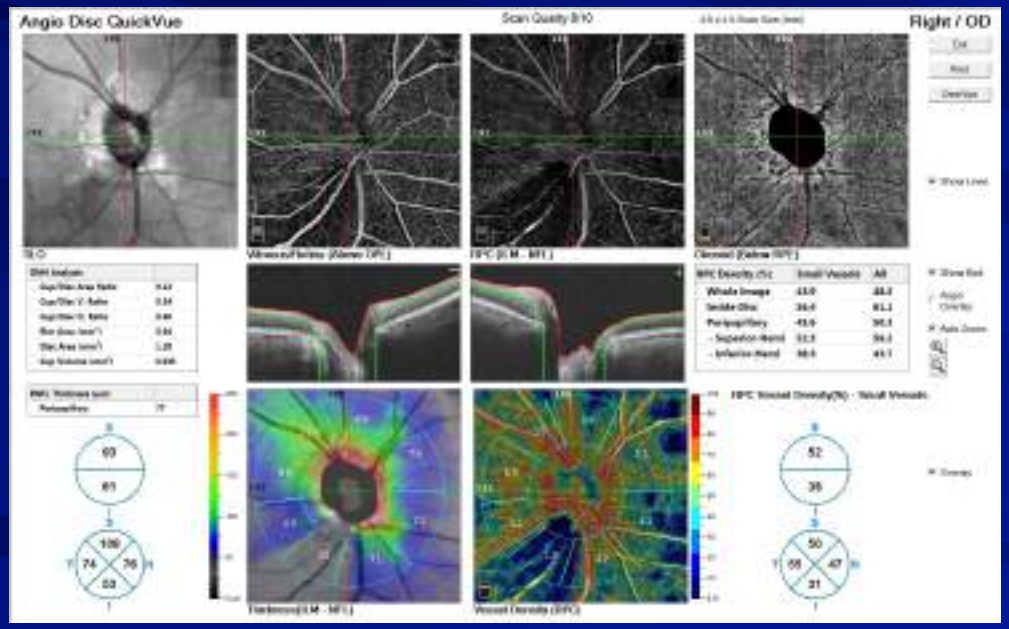

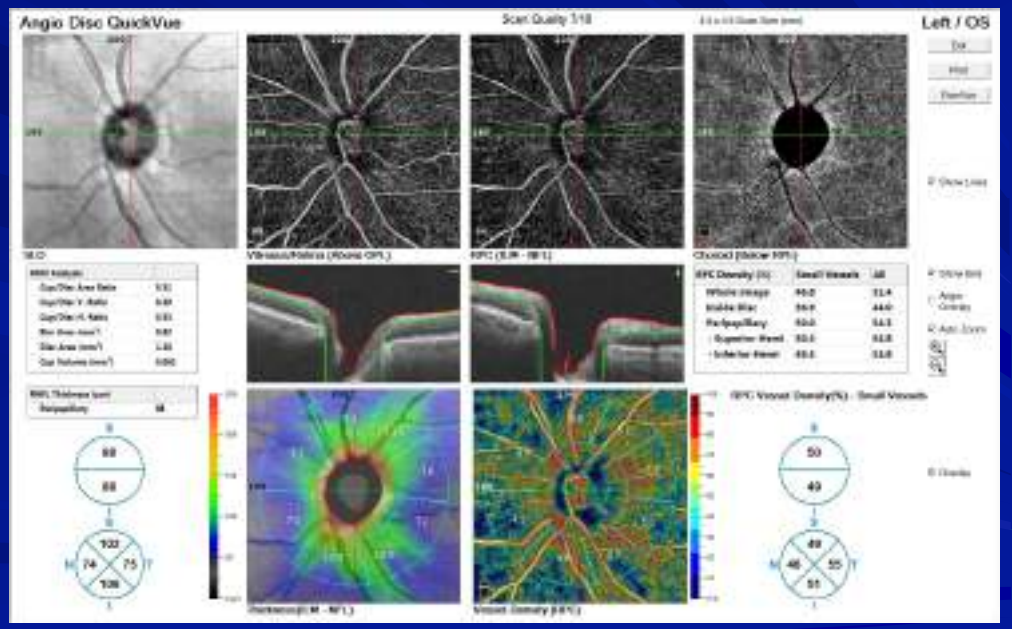

Hope You Enjoyed
Thank You!

Greg